



RESEARCH ARTICLE

Three-dimensional reconstruction from computed tomography images of respiratory system in New Zealand rabbits

Mustafa Orhun Dayan*, Kamil Besoluk

Özet

Dayan MO, Beşoluk K. Yeni Zelanda tavşanlarında solunum sisteminin bilgisayarlı tomografi görüntülerinin üç boyutlu hale getirilmesi. *Eurasian J Vet Sci*, 2011, 27, 3, 145-148

Amaç: Çalışmanın amacı solunum sistemi organlarının bilgisayarlı tomografi görüntülerinden üç boyutlu görüntü ve biyometrik değerler elde edilmesini sağlamaktır.

Gereç ve Yöntem: Araştırmada 6 adet Yeni Zelanda tavşanı kullanıldı. Tavşanların yüzükoyun pozisyonda iken genel anestezi altında bilgisayarlı tomografi görüntüleri alındı. Bilgisayarlı tomografiden elde edilen axial görüntüler DICOM formatında kaydedildi. MIMICS® 12.1 bilgisayar programı kullanılarak üç boyutlu rekonstrüksiyon işlemi gerçekleştirildi. Solunum sistemi organlarının hacim ve yüzey alanı program yardımıyla otomatik olarak hesaplandı.

Bulgular: Solunum sistemi organlarının yüzey alanı ve hacmi sırasıyla 22447 mm² ve 68028 mm³ olarak tespit edildi.

Öneri: Bu çalışmada kullanılan teknolojiden elde edilen sonuçlar anatomi biliminde yeni araştırmalar ve yaklaşımlara kaynak olabilir.

Abstract

Dayan MO, Besoluk K. Three-dimensional reconstruction from computed tomography images of respiratory system in New Zealand rabbits. *Eurasian J Vet Sci*, 2011, 27, 3, 145-148

Aim: The aim of this study was to produce three-dimensional reconstructions of organs of the respiratory system obtained from computed tomography images, and also to determine the biometric parameters of the organs studied.

Materials and Methods: A total of 6 New Zealand white rabbits were used. Computed tomographic imaging was performed under general anaesthesia with the rabbits in the prone position. Axial images obtained from computed tomography were stored in DICOM format. Three-dimensional reconstructions were produced using MIMICS® 12.1 computer software. The volume and surface area of the organs of the respiratory system were calculated automatically by the software.

Results: The surface area and the volume of the respiratory system were 22447 mm² and 68028 mm³, respectively.

Conclusion: The results obtained using the technology applied in this study may be a key to future investigations and to a new approach to anatomical science.

Department of Anatomy, Faculty of Veterinary Medicine,
University of Selçuk, Campus, 42075, Konya, Turkey

Received: 08.12.2010, Accepted: 20.05.2011

*modayan@selcuk.edu.tr

Anahtar kelimeler: Bilgisayarlı tomografi, üç boyutlu
yapılandırma, solunum sistemi, tavşan

Keywords: Computed tomography, three dimensional
reconstruction, respiratory system, rabbit

► Introduction

Medical imaging is the most significant foundation of anatomical and clinical research (Patias 2002). In the recent years, many new imaging techniques such as computed tomography (CT), magnetic resonance and single photon emission computed tomography have been developed (Lewis et al 2002). CT is the most preferred method for imaging of the lung because of its resolution and speed (Simon 2000). These imaging techniques can be used successfully in veterinary field, specifically imaging of small animals (Lewis et al 2002). CT can produce excellent diagnostic images of organs when compared to other imaging techniques (Schwarz and Tidwell 1999).

Three dimensional (3D) measurement techniques are approved to be used in human health and veterinary science including anatomy, orthopaedics, dentistry, surgery, pulmonary atelectasis, primary lung tumours etc. These techniques are also applicable in diagnosis of cancer and pregnancy (Elad and Einav 1990, Cipone et al 2003, Eslaminejad et al 2006, Karabork 2009). 3D software programs are used in human medicine such as otolaryngology (Chen et al 2009), orthopaedic surgery (Mahaisavariya et al 2002) and bioengineering (Gittard et al 2009). Especially in the orthopaedic surgery, 3D programs can be used for the design of proper size of prostheses (Mahaisavariya et al 2002). One of the programs that used for this purpose is the MIMICS® 12.1 which is also successfully used in veterinary medicine for the past few years (Kimura et al 2005, Guan et al 2006, Henry et al 2007, Gittard et al 2009, Lu et al 2009).

Many rabbit breeds are used as pet, laboratory animal or in the textile industry. Diseases of rabbits show a significant challenge for veterinary practitioners since many disorders are diagnose at very late stage. Amongst these diseases, lung infections may be missed during clinical examination. Moreover rabbits are used as important model for studying pathogenesis of *C. pneumoniae* infection (Fong et al 1997, Meredith and Crossley 2002, Altan and Goksahin 2011).

The aim of this study was to exhibit 3D reconstructions of respiratory system organs obtained from CT images, and also to show biometric parameters of the related organs.

► Materials and Methods

A total of 6 adult New Zealand white rabbits (8-10 months, 2100-2400 g, 3 males, 3 females obtained from Cukurova University, TIPDAM, Adana, Turkey) were used. The study protocol was approved by The Ethics Committee of the Veterinary Faculty. Animals were anaesthetized with combination of xylazine (5 mg/kg, IM, Rompun® inj, Bayer Veteriner Ilac San., Istanbul, Turkey) and ketamine (40 mg/kg, IM, Ketasol® inj, Interhas Veteriner Ilaclari, Ankara, Turkey), then imaged with multislice CT (Somatom Sensation, Siemens Medical Solutions, Forchheim, Germany). Axial images obtained from CT were stored at DICOM formats. 3D reconstructions were achieved by MIMICS® 12.1 (The Materialise Group, Leuven, Belgium) computer software. Volume and surface area of respiratory system were calculated by automatically with computer software.

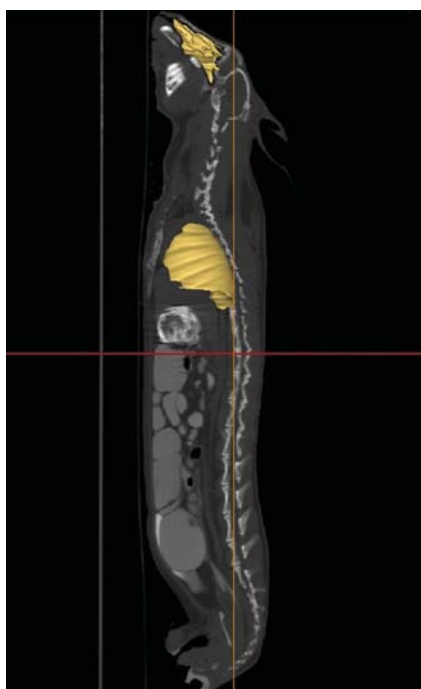

Figure 1. Nasal cavity and lung, left view.

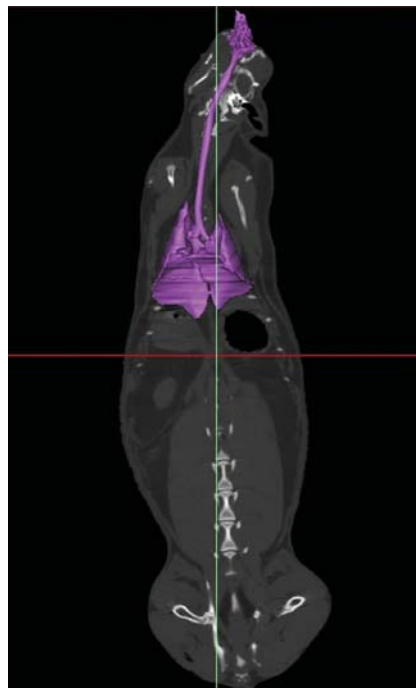


Figure 2. Respiratory system, ventral view.

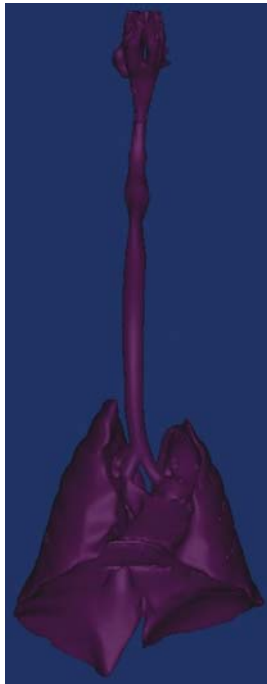

Figure 3. Respiratory system, ventral view.

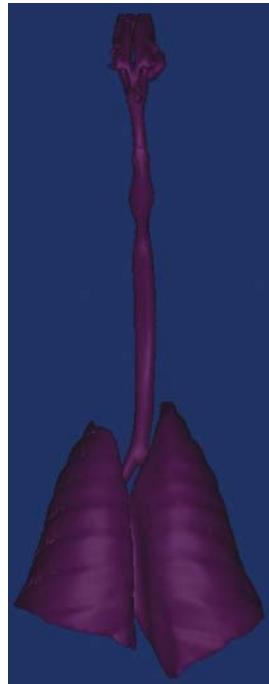

Figure 4. Respiratory system, dorsal view.

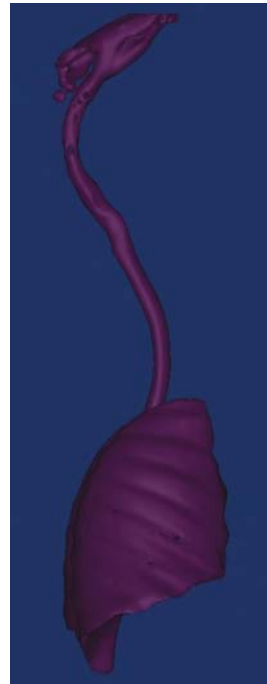

Figure 5. Respiratory system, right-lateral view.



Figure 6. Respiratory system, left-lateral view.

Volumes and surface areas of respiratory system are expressed as mean \pm SEM.

► Results

3D imaging of respiratory system was shown in Figures (1-6). Volume, surface area and portion of volume/area were found 68028 ± 6313 mm³, 22447 ± 1073 mm² and 2.99 ± 0.14 , respectively.

► Discussion

The most morphometric studies have been conducted in rodents. Radiological techniques used on rabbits can diagnose many conditions, such as dental diseases, fractures, pregnancy, tumors and pneumonia (Merkus et al 1996, Huerkamp 2003, Durgut and Yarsan 2007).

Some images gained from CT can be transferred from 2D to 3D (Gittard et al 2009, Lu et al 2009). The 3D images may be valuable criteria for clinical treatment (Elad and Einav 1990, Mitchell 1995). In the current study, the MIMICS® 12.1 is used to obtain 3D imaging. This program was used for reconstruction of (Guan et al 2006), vertebra lumbalis (Lu et al 2009), os scaphoideum and os lunatum (Gittard et al 2009), and the stomach (Henry et al 2007). Although MIMICS® 12.1 is used in human medicine (Gittard et al 2009), our study is the first research in veterinary area according to recent literature. 3D reconstructed lung model obtained from CT images can create realistic organ (Henry et al 2007). 3D imaging of respiratory system was shown in Figures. Volume, surface area and portion of volume/area were found 68028 ± 6313

mm³, 22447 ± 1073 mm² and 2.99 ± 0.14 , respectively. There have been very limited studies in the literature. In one study, lung volume (except the trachea and sinuses) was reported as 24900 mm³ in human infants (Thome et al 1998).

► Conclusions

In conclusion, 3D reconstruction of CT images can serve as the biggest advantages in the veterinary medicine. This technique can provide correct measurements of organs and may lead to 3D anatomical databases with tissue specific color. Hence these data can be used anatomical reconstructions in anatomy education and surgery science.

► References

- Altan S, Goksahin E, 2011. Incisor malocclusions in a rabbit. *Eurasian J Vet Sci*, 27, 135-137.
- Chen XB, Lee HP, Chong VF, Wang de Y, 2009. Assessment of septal deviation effects on nasal air flow: a computational fluid dynamics model. *Laryngoscope*, 119, 1730-1736.
- Cipone M, Diana A, Gandini D, Fava D, Trenti F, 2003. Use of computed tomography in thoracic diseases of small animals. *Vet Res Commun*, 27 Suppl 1, 381-384.
- Durgut R, Yarsan E, 2007. *Laboratuvar Hayvanları Hastalıkları ve Sağaltımı*, Medisan, Ankara, Turkey.
- Elad D, Einav S, 1990. Three-dimensional measurement of biological surfaces. *ISPRS J Photogramm*, 45, 247-466.
- Eslaminejad MR, Valojerdi MR, Yazdi PE, 2006. Computerized three-dimensional reconstruction of cartilage canals in chick tibial chondroepiphysis. *Anat Histol Embryol*, 35, 247-252.

- Fong IW, Chiu B, Viira E, Fong MW, Jang D, Mahony J, 1997. Rabbit model for Chlamydia pneumoniae Infection. *J Clin Microbiol*, 35, 48-52
- Gittard SD, Narayan RJ, Lusk J, Morel P, Stockmans F, Ramsey M, Laverde C, Phillips J, Monterio-Riviere NA, Ovsianikov A, Chichkov BN, 2009. Rapid prototyping of scaphoid and lunate bones. *Biotechnol J*, 4, 129-34.
- Guan Y, Yoganandan N, Zhang J, Pintar FA, Cusick JF, Wolfla CE, Maiman DJ, 2006. Validation of a clinical finite element model of the human lumbosacral spine. *Med Bio Eng Comput*, 44, 633-641.
- Henry JA, O'Sullivan G, Pandit AS, 2007. Using computed tomography scans to develop an ex-vivo gastric model. *World J Gastroenterol*, 13, 1372-1377.
- Huerkamp MJ, 2003. The Rabbit, in: *Exotic Animal Medicine for the Veterinary Technician*, Eds; Ballard B, Cheek R, Iowa State Press, Iowa, USA.
- Karabork H, 2009. Three-dimensional measurements of glenohumeral joint surfaces in sheep, cat and rabbit by photogrammetry. *JAVA*, 8, 1248-1251.
- Kimura J, Hirano Y, Takemoto S, Nambo Y, Ishinazaka T, Himeno R, Mishima T, Tsumagari S, Yokota H, 2005. Three-dimensional reconstruction of the equine ovary. *Anat Histol Embryol*, 34, 48-51.
- Lewis JS, Achilefu S, Garbow JR, Laforest R, Welch MJ, 2002. Small animal imaging: current technology and perspectives for oncological imaging. *Eur J Cancer*, 38, 2173-2188.
- Lu S, Xu YQ, Zhang YZ, Li YB, Xie L, Shi JH, Guo H, Chen GP, Chen YB, 2009. A novel computer-assisted drill guide template for lumbar pedicle screw placement: a cadaveric and clinical study. *Int J Med Robotics Comput Assist Surg*, 5, 184-191.
- Mahaisavariya B, Sitthiseripratip K, Tongdee T, Bohez EL, Vander Sloten J, Oris P, 2002. Morphological study of the proximal femur: a new method of geometrical assessment using 3-dimensional reverse engineering. *Med Eng Phys*, 24, 617-622.
- Meredith A, Crossley DA, 2002. Rabbits, in: *Manual of Exotic Pets*, Eds; Meredith A, Redrobe S., 4th edition, BSAVA, Hampshire, UK.
- Merkus, PJFM, ten Have-Opbroek AAW, Quanjer PH, 1996. Human lung growth: A review. *Pediatr Pulmonol*, 21, 383-397
- Mitchell HL, 1995. Applications of digital photogrammetry to medical investigations. *ISPRS J Photogramm*, 50, 27-36.
- Patias P, 2002. Medical imaging challenges photogrammetry. *ISPRS J Photogramm*, 56, 295-310
- Schwarz LA, Tidwell AS, 1999. Alternative imaging of the lung. *Clin Tech Small Anim Pract*, 14, 187-206.
- Simon BA, 2000. Non-invasive imaging of regional lung function using X-ray computed tomography. *J Clin Monit*, 16, 433-442.
- Thome U, Topfer A, Schaller P, Pohlandt F, 1998. Comparison of lung volume measurements by antero-posterior chest x-ray and the sf6 washout technique in mechanically ventilated infants. *Pediatr Pulmonol*, 26, 265-272.