



RESEARCH ARTICLE

Carvacrol alleviates acrylamide-induced hepatotoxicity in rats: An Experimental insights

Aysegul Bulut¹, Goktug Senturk², Durmus Hatipoglu³, Mehmet Burak Ates¹

¹Selcuk University, Veterinary Faculty, Department of Pathology, Konya, Türkiye
²Aksaray University, Veterinary Faculty, Department of Physiology, Aksaray, Türkiye
³Selcuk University, Veterinary Faculty, Department of Physiology, Konya, Türkiye

Received: 27.09.2023 , Accepted: 21.11.2023

*drhatip@selcuk.edu.tr

Karvakrol sıçanlarda akrilamidin neden olduğu hepatotoksisiteyi hafifletir: DeneySEL bir bakış

Eurasian J Vet Sci, 2023, 39, 4, 177-184
DOI: 10.15312/EurasianJVetSci.2023.415

Öz

Amaç: Bu çalışmada, akrilamid (AA) kaynaklı hepatotoksosite üzerine karvakrolün (CRV) rat karaciğeri üzerine koruyucu etkilerinin araştırılması amaçlanmıştır.

Gereç ve Yöntem: Çalışmada toplam 30 adet Wistar Albino rat kullanıldı. Ratlar; Kontrol (n:6), CRV (n:8, 50 mg/kg/gün karvakrol, i.p.), AA (n:8, 40 mg/kg/gün akrilamid, gavaj) ve AA+CRV (n:8, 40 mg/kg/gün akrilamid, gavaj + 50 mg/kg/gün karvakrol i.p) olmak üzere 4 gruba ayrıldı. 15 günlük deneysel çalışmanın ardından anestezi altında kan örnekleri alınan hayvanlara ötanazi uygulanarak nekropsileri yapıldı. Serum örneklerine karaciğer fonksiyon testleri uygulandı. Aynı zamanda histolojik analiz, skorlama ve hematoksilen-eozin boyama için karaciğer dokuları %10'luk formaldehit solüsyonunda tespit edildi.

Bulgular: Mikroskopik incelemede; AA'nın hidropik dejenerasyon, yağlanma, nekroz/apoptoz, safra kanalı proliferasyonu, dissosiasyon, konjesyon, megalositosis ve mononükleer hücre infiltrasyonlarına neden olduğu tespit edildi. Buna paralel olarak ALT, AST ve ALP düzeylerinde AA kaynaklı artışlar tespit edildi. Diyete CRV eklenmesiyle histolojik yapı ve karaciğer fonksiyon testleri önemli ölçüde iyileşti. Bu bulgular, CRV'nin AA'nın neden olduğu karaciğer hasarını iyileştirerek hepatoprotektif etkiye sahip olduğunu ortaya koydu.

Öneri: Bu çalışma CRV'nin AA kaynaklı karaciğer hasarını hafiflettiğini gösterdi. Karaciğer hasarını önleyici etkisinin antioksidan özelliğinden kaynaklandığı düşünülmektedir. Ancak spesifik mekanizmanın moleküler düzeyde belirlenmesi ve terapötik yönetim önerilerinin sunulması için daha fazla araştırmaya ihtiyaç vardır.

Anahtar kelimeler: Antioksidan, karaciğer, kekik, hepatoprotektif, oksidatif stres,

Abstract

Aim: This study aimed to investigate the protective effects of carvacrol (CRV) on rat liver against acrylamide (AA)-induced hepatotoxicity.

Materials and Methods: A total of 30 Wistar Albino rats were used in the study. Rats were divided into 4 groups: Control (n:6), CRV (n:8, 50 mg/kg/day carvacrol, i.p), AA (n:8, 40 mg/kg/day acrylamide, gavage) and AA+CRV (n:8, 40 mg/kg/day acrylamide, gavage + 50 mg/kg/day carvacrol i.p). At the end of the 15-day study period, the rats, whose blood samples were taken under anesthesia, were euthanized and necropsied. Liver function tests were examined from serums. At the same time for histological analysis, scoring, and hematoxylin-eosin staining, liver tissues were preserved in 10% formaldehyde solution.

Results: In microscopic examination, it was determined that AA causes hydropic/vacuolar degeneration, fatty changes, necrosis/apoptosis, bile duct proliferation, hepatic cord dissociation, congestion, megalocytosis and mononuclear cell infiltration. Parallely, AA raised the levels of ALP, AST, and ALT. The inclusion of CRV to the diet improved histological structure and liver function tests considerably. These results show that CRV has a hepatoprotective effect by reducing AA-induced liver damage.

Conclusion: This study showed that CRV attenuated AA-induced liver injury. It is considered that its preventive effect against liver damage is due to its antioxidant properties. However, more research is needed to determine the specific mechanism at the molecular level and offer therapeutic management suggestions.

Keywords: Antioxidants, hepatoprotective, liver, oxidative stress, thyme

CITE THIS ARTICLE: Bulut, Senturk, Hatipoglu and Ates 2023. Carvacrol alleviates acrylamide-induced hepatotoxicity in rats: An Experimental insights Eurasian J Vet Sci, 39, 4, 177-184



Introduction

Acrylamide (AA) is an odorless, white, crystalline compound with a polar structure, readily soluble in water, ether, chloroform, ethanol, and methanol (Posta 2021). AA exhibits carcinogenic and mutagenic effects (Öztürk 2023). Although it is a synthetic compound that has been used in various industrial areas (water treatment, textile and cosmetic industries, etc.) since 1950, it is also a compound formed during the cooking stages of foods (Koszucka et al 2020, Pekmez 2020). AA emerges as a byproduct of the Maillard reaction, a chemical process occurring in carbohydrate-rich foods cooked at high temperatures (Kowalska et al 2017). The most important sources of exposure to AA are foods and drinking water (Svensson et al 2003, Bušová et al 2020, Hatipoğlu et al 2023). Cigarette smoke contains it as well (Mojska et al 2016). AA is taken into through skin, respiration and digestion and spreads to all tissues, especially the liver. While most of AA (90%) is metabolized, the remaining part is excreted in the urine (Semla et al 2017, Kopanska et al 2018, Mollakhalili-Meybodi et al 2021). Recognized as a carcinogenic substance for human health by the International Agency for Research on Cancer (IARC) in 1994, AA is released during cooking and frying processes (Powers et al 2013).

The liver, responsible for detoxifying chemicals, alcohol, and drugs, plays a crucial role in AA metabolism. AA can be directly metabolized by glutathione in the liver or converted to glycidamide (GA), the epoxide form of AA, through the cytochrome P-450 CYP2E1 enzyme system. Subsequently, GA is enzymatically metabolized by glutathione (GSH) (Paulsson et al 2005, Kwolek- Mirek et al 2011). AA toxications are caused by this epoxide form GA, which is formed as a result of its metabolism (Kim et al 2015). Approximately 6% of AA taken into the body is converted to GA (Koszucka et al 2020). AA detoxification reduces glutathione (GSH), SOD and peroxidase activities. It also increases the amount of MDA, which is an indicator of lipid peroxidation level and liver damage (Allam et al 2010, Abdel-Daim et al 2020). Thus, AA induces oxidative stress and causes cytotoxicity (Nan et al 2021). AA and its derivatives, having a short half-life, are mostly excreted through urine (Öztürk 2023). AA, with its increasing use in many industrial sectors, has drawn attention as a carcinogenic, neurotoxic, and reproductively toxic chemical to which humans are exposed. Despite the well-understood metabolism of AA, its complete toxic effects on the liver remain elusive.

In an era witnessing an escalation in exposure to toxic substances, resulting in an upswing in organ failures, various therapeutic strategies have been developed to mitigate the side effects of toxic agents like AA. Researchers have conducted studies using protective compounds such as thymoquinone, resveratrol, curcumin, crocin, and

N-acetylcysteine, reporting positive outcome (Altinoz et al 2015, Gedik et al 2017, Ranjini and Manonmani 2019, Sun et al 2020, Ghonim 2023). CRV is a phenolic compound found in thyme oil that is soluble in solvents such as ethanol and acetone. CRV, which is used as a preservative in the food industry, has antioxidant, antibacterial, antiviral, and antitumoral activities (Sharifi-Rad et al 2018). This current study aims to pathologically assess the effects of CRV, with its numerous positive attributes, on AA-induced hepatotoxicity.

Material and Methods

Animals and ethics statement

Thirty healthy adult Wistar Albino rats weighing 250-300 g were used in the investigation. The experiment terminated 15 days. All experimental protocols followed the European Economic Community Directives on animal welfare (86/609/CEE and 2010/63/EU). During the study, rats were housed in cages with a 12-hour day and 12-hour night light cycle, a temperature of 22±2 °C in the room and 50±10% humidity.

Experimental design

The study included 30 Wistar Albino rats in total. There were four groups of rats: Control (n:6), CRV (n:8, 50 mg/kg/day carvacrol, i.p), AA (n:8, 40 mg/kg/day acrylamide, gavage) and AA+CRV (n:8, 40 mg/kg/day acrylamide, gavage + 50 mg/kg/day carvacrol i.p). During the experiment, standard rat food and drinking water were given ad libitum. After the 15-day experiment, all animals were euthanized and necropsied under sedation (10mg/kg xylazine and 90 mg/kg ketamine) following the determination of their body weights. The blood was collected in serum (BD Vacutainer SSTTM II Advance-367953) tubes and centrifuged at 4500 rpm for 10 min at +4°C (Hettich Universal 32R). Serum samples were stored at -80 °C in Eppendorf tubes until analysis.

Measurement of Liver Function Test (LFT) Enzyme Activities

To examine AA-induced liver toxicity and the hepatoprotective effects of CRV, some necessary LFT enzyme analyzes were performed in serum. The standard protocol of Reitman and Frankel (1957) was used to measure aspartate aminotransferase (AST) and alanine aminotransferase (ALT) activity. Alkaline phosphatase (ALP) activity was measured with the Wenk and Fernandis (2007) protocol. AST, ALT, and ALP activity were given in IU/mL serum.

Relative liver weight

The rats were euthanized after their live weights were weighed. Then liver samples dissected and weighed. The formula was used to find the relative liver weights; Liver weight x 100 / body weight (Ates et al 2022).



Macroscopic and histopathological examination

Macroscopic examination of liver samples was carried out. Livers after macroscopic examination were fixed in 10% formaldehyde solution for 24 hours. In order to get rid of the fixation solution, tissues were rinsed under tap water for 12 hours. Routine tissues processing procedure were performed on a device (LeicaTP1050). Then, 5-micron thick sections were cut from the paraffin-embedded tissues with a microtome (Leica RM2120). The sections were stained with hematoxylin-eosin, which is a routine staining method, and examined under a light microscope (Olympus BX51, Tokyo, Japan). Hydropic/vacuolar degeneration, necrosis/apoptosis, bile duct hyperplasia (BDH), hepatic cord dissociation (HCD), congestion, Kupffer cell activation (KCA), karyomegaly and mononuclear cell infiltration (MCI) in at least five distinct areas were examined through a microscope. The severity and frequency of findings (0): no lesion, (1): 1-25 percent, (2) 26-50 percent, (3): 51-75 percent and (4): 76-100 percent (Ateş and Hatipoğlu 2022). After summing the total liver lesion score was determined using the numerical values attributed to degenerative findings.

Statistics analysis

The numerical values obtained as a result of scoring were analyzed in the IBM SPSS Statistics 22 program. The Shapiro-Wilk test was used to examine whether the data was normally distributed, and the homogeneity of the data was checked with Levene's test. One Way Anova and post hoc Duncan test were applied to the data that were found to comply with normal distribution. The results were given as mean \pm standard error of the mean, with $P < 0.05$ indicating significance.

Results

Measurement of Liver Function Test (LFT) Enzyme Activities

According to the results of this study, it was assigned that AA caused hepatotoxicity by causing a significant increase in liver enzyme levels (ALT, AST and ALP). On the other hand, CRV, whose therapeutic efficacy was analysed, was observed to reduce the increase in these enzyme levels and promote the protective activity of the liver (Figure 1).

Relative liver weights

Table 1 indicates the relative liver weights determined by proportioning the % live weights of the replicates in the groups. According to these data, a substantial increase in liver weights was detected in the AA and AA+CRV groups compared to the control group ($P < 0.05$). No statistical difference was observed between the control group and CRV group ($P > 0.05$).

Table 1. Relative liver weights

Groups	Relative liver weight
Control	3,19 \pm 0,24 ^a
AA	4,36 \pm 0,15 ^b
AA+CRV	4,04 \pm 0,14 ^b
CRV	3,76 \pm 0,24 ^a

^{abc} Values with different superscripts in the same column indicate that the difference is statistically significant ($p < 0.05$, one-way ANOVA post hoc Duncan test).

Macroscopic and histopathological findings

Degenerative changes were observed in the livers of the AA and AA+CRV groups, characterized by enlargement, blunting of the edges, and a dull grayish brown appearance. No macroscopic changes were found in the control and CRV groups.

It was carried out for each case in terms of hydropic/vacuolar degeneration, fatty changes, necrosis/apoptosis, bile duct hyperplasia (BDH), hepatic cord dissociation (HCD), congestion, Kupffer cell activation (KCA), megalocytosis and mononuclear cell infiltration. Then, the findings were scored separately, and the total lesion score was determined (Table 2). When the outcomes were analyzed, the histological structure was observed to be normal in the control group (Figure 2A). Hydropic/vacuolar degeneration, fatty changes, necrosis/apoptosis, HCD, congestion, megalocytosis, KCA and MCI were considerably increased in the AA group compared to the control group ($P < 0.05$). The degenerative and necrotic/apoptotic changes that occurred were mostly centrilobular (Figure 2B, Figure 3). The concurrent application of acrylamide with carvacrol was found to significantly improve all parameters, as illustrated in Figure 2D. No difference was found in the groups given CRV compared to the healthy control group ($P > 0.05$) (Figure 2A,C).

Discussion

Acrylamide, a low molecular weight toxic compound, finds frequent use in various industries (Boyacı 2012). It is also formed by heating carbohydrate-rich foods (Arusoğlu 2015). It enters the body via digestion, respiration, and the skin. AA, which can be transmitted to the offspring through the placenta and milk, causes many toxic effects such as hepatotoxicity. The cause of acrylamide toxicity is reactive oxygen species released during its metabolism. GA, released as a result of metabolism with cytochrome P450 and glutathione, is more dangerous than AA and significantly increases oxidative stress by disrupting enzyme activity (Teodor et al 2011, Sayed et al 2022). In this study, our aim was to ascertain the protective effects of carvacrol, the active ingredient in thyme, on the liver in rats administered acrylamide, evaluating serum biochemical parameters and pathological findings, including relative organ weight and histopathology.



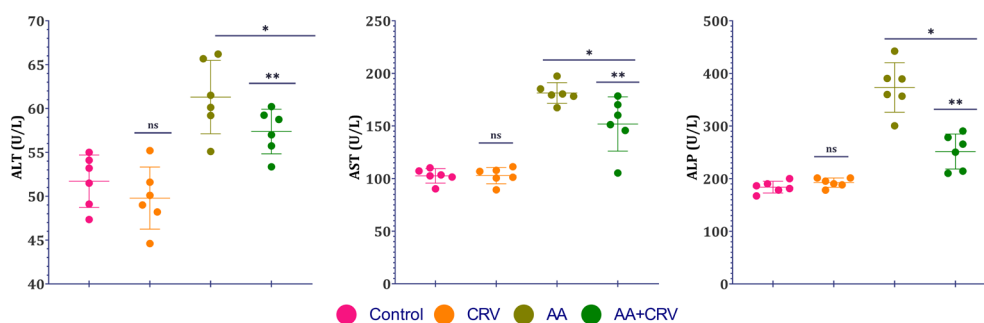


Figure 1. Effect of AA and CRV on Serum Liver Function Test (LFT) Enzymes. Aspartate transaminase (AST), alanine transaminase (ALT), and alkaline phosphatase (ALP) values are expressed as IU/mL of rat serum samples.

Liver function tests (LFT), crucial for determining serum enzyme concentrations like ALT, AST, and ALP, play a pivotal role in liver histopathological examinations and hepatotoxicity assessment (Tian et al. 2019). ALT and AST enzymes, the most critical indicators of hepatocellular damage, are found in high concentrations in the liver. Concentrations of ALT and AST enzymes in the liver vary regionally. AST is high in hepatocytes located in the 3rd region of the liver (periportal). ALT is higher in hepatocytes located in the periportal area. This difference may be an indicator of the region where liver damage is concentrated (Rej 1989, Moshtaghi et al 2003, Center 2007, Goorden et al 2013). ALP is an enzyme that can be synthesized from other tissues, especially the liver (Kantar 2017). AST is both a cytosolic and mitochondrial enzyme. ALT is primarily found in the cytosol and is most abundant in the liver tissue, making it a more specific indicator of liver damage (Lott and Wolf 1986). ALP is found in the canalicular membrane of hepatocytes (Kaplan 1986). In a research by Bin-Jumah et al (2021), they observed a significant increase in the serum levels of ALT, AST and ALP enzymes. In the biochemical results of our study, increases in serum ALT, AST and ALP levels of rats exposed to AA were observed. The reason for this was thought to be the impaired membrane integrity as a result of AA-induced increased ROS accumulation in hepatocytes affecting mitochondrial energy metabolism. In addition, CRV, whose therapeutic efficacy was evaluated, was found to reduce the increase observed in enzyme levels with simultaneous administration with AA. This result was interpreted as protective activity of CRV against AA-induced liver damage.

There are studies reporting changes in relative liver weight as a result of AA exposure (Banc et al 2022, Tomaszewska et al 2022). In our study, increases in relative liver weight were also detected as a result of AA exposure compared to the control group. It was thought that the reason for this situation observed in the AA and AA+CRV groups was due to hydropic degeneration, steatosis, congestion and mononuclear cell infiltration in the liver.

The toxic effect of acrylamide on the liver is attributed to cellular damage caused by oxidative stress resulting from its biotransformation (Zhao et al 2015a, Zhang et al 2023). An accumulation of reactive oxygen species in hepatocytes is caused by AA. As a result of this accumulation, it causes hepatotoxicity by reducing the release of antioxidant enzymes and antioxidant genes (Zhao et al 2015b). Increased ROS accumulation in hepatocytes affects mitochondrial energy metabolism, causing hydropic/vacuolar degeneration and necrosis/apoptosis (Iwakiri 2015). In the current study, it was interpreted that the observed liver abnormalities, including single-cell necrosis/apoptosis and hydropic degeneration, mostly concentrated in the centrilobular region, may be caused by acrylamide-induced ROS increase and DNA damage (Besaratnia and Pfeifer 2004).

Nan et al (2021) reported that AA increased Kupffer cell activation. Toxic substances activate these cells, causing ROS production and secretion of cytokines such as nitric oxide (NO) and TNF-alpha. These cytokines trigger the inflammatory response (Wheeler 2003). Mahmood et al (2015) detected congestion and mononuclear cell infiltration in vessels in the sinusoidal and portal sections in a study evaluating the effects of AA on the liver. In our investigation, we also found an increase in the number of Kupffer cells. It was thought that enhanced cytokine release produced mononuclear cell infiltration as a result of this increase (Mahmood et al 2015). It has been reported that AA causes dissociation in Remark cords (Zhao et al 2020). Bile duct hyperplasia and obstruction may also occur as a result of hepatotoxicity. Chronic toxications cause megalocytosis in hepatocytes (Metin 1989, Greaves 2012). Macro-microvesicular steatosis is observed in hepatocytes as a result of exposure to chemical substances such as carbon tetrachloride and orotic acid (Atasever et al 2020). Small drops of steatosis in hepatocytes are generally observed in acute metabolic and toxic events (Erer et al 2009). In our study, congestion findings were found in the portal and sinusoidal areas. It was determined that the cause of dissociation in Remark cords was congestion occurring in sinusoidal areas, and it was also observed that atrophy occurred in hepatocytes due

Table 2. Histopathological results

Groups	Hydropic/ vacuolar degeneration	Fatty changes	Necrosis/ Apoptosis	BDH	HCD	Congestion	Megalocytosis	MCI	KCA	Total Score
Control	0,33±0,10 ^a	0,25±0,11 ^a	0,33±0,11 ^a	0,58±0,08 ^{ab}	0,25±0,11 ^a	0,16±0,10 ^a	0,33±0,10 ^a	0,58±0,08 ^a	0,33±0,24 ^a	3,91±0,71 ^a
AA	2,33±0,16 ^c	2,08±0,23 ^c	2,83±0,16 ^c	2,16±0,21 ^c	2,58±0,15 ^c	2,33±0,21 ^c	2,25±0,25 ^b	1,66±0,24 ^c	1,66±0,33 ^b	21,33±1,61 ^c
AA+CRV	1,00±0,18 ^b	0,75±0,11 ^b	1,75±0,17 ^b	0,91±0,08 ^b	1,75±0,17 ^b	1,00±0,18 ^b	1,83±0,16 ^b	1,08±0,08 ^b	2,08±0,20 ^b	14,75±0,68 ^b
CRV	0,83±0,16 ^{ab}	0,58±0,08 ^{ab}	0,91±0,08 ^a	0,50±0 ^a	0,58±0,08 ^a	0,41±0,15 ^a	0,66±0,10 ^a	0,58±0,08 ^a	0,58±0,08 ^a	6,66±0,20 ^a

^{a,b,c,d} Values with different superscripts in the same column indicate that the difference is statistically significant ($p < 0.05$, one-way ANOVA post hoc Duncan test). BDH: Bile duct hyperplasia; HCD: Hepatic cord dissociation; MCI: mononuclear cell infiltration, KCA: Kupffer cell activation.

to the pressure resulting from congestion. It was postulated that AA provoked irritation of the bile duct surface, thus triggering bile duct hyperplasia as a defensive response. It was determined that the finding of megalocytosis was observed as a result of acute toxicity caused by AA. It has been reported that oral AA administration causes liver damage characterized by liver activation, hepatocyte degeneration, necrosis/apoptosis, enlargement of sinusoidal areas, congestion and mononuclear cell infiltration (Al-Mosaibih 2013, Sinan et al 2018). In the current study, similar to the literature, it was histopathologically shown that AA caused hepatocyte degeneration, steatosis, necrosis/apoptosis, bile duct hyperplasia, hepatic cord dissociation, congestion, megalocytosis, mononuclear cell infiltration, liver activation and increased the total liver lesion score.

The research aimed to assess the protective effects of CRV against acrylamide-induced hepatotoxicity. Existing data suggests that CRV prevents liver damage by reducing lipid peroxidation severity and preserving hepatocyte structural integrity (Suntres et al 2015, Baranauskaitė et al 2020, Gursul

et al 2022). CRV is reported to have a hepatoprotective effect by reducing oxidative stress, decreasing ROS accumulation, and enhancing the release of antioxidant genes and enzymes (Gursul et al 2019, Tohidi et al 2020). In the current study, it is determined that CRV causes decreases in the rate of hepatocyte degeneration as a result of its hepatoprotective effect. It is thought to protect hepatocytes against hydropic degeneration by reducing ROS accumulation and increasing the release of antioxidant genes and enzymes. CRV has anti-inflammatory activity. It shows this effectiveness by reducing the amount of pro-inflammatory cytokines produced and released in Kupffer cells (Alvarenga et al 2016). In this study, the observed decrease in mononuclear cell infiltration was thought to be due to the decrease in the number of Kupffer cells. It has been reported that CRV has an antiapoptotic effect by reducing cytochrome c, caspase-3 and Bax levels (Yesildag et al 2022). The decrease in the level of necrosis/apoptosis in this study was also attributed to this activity of CRV. As a result, it was determined that CRV provided improvements in hepatocyte degeneration, necrosis/apoptosis, bile duct hyperplasia, congestion, liver activation and total liver lesion

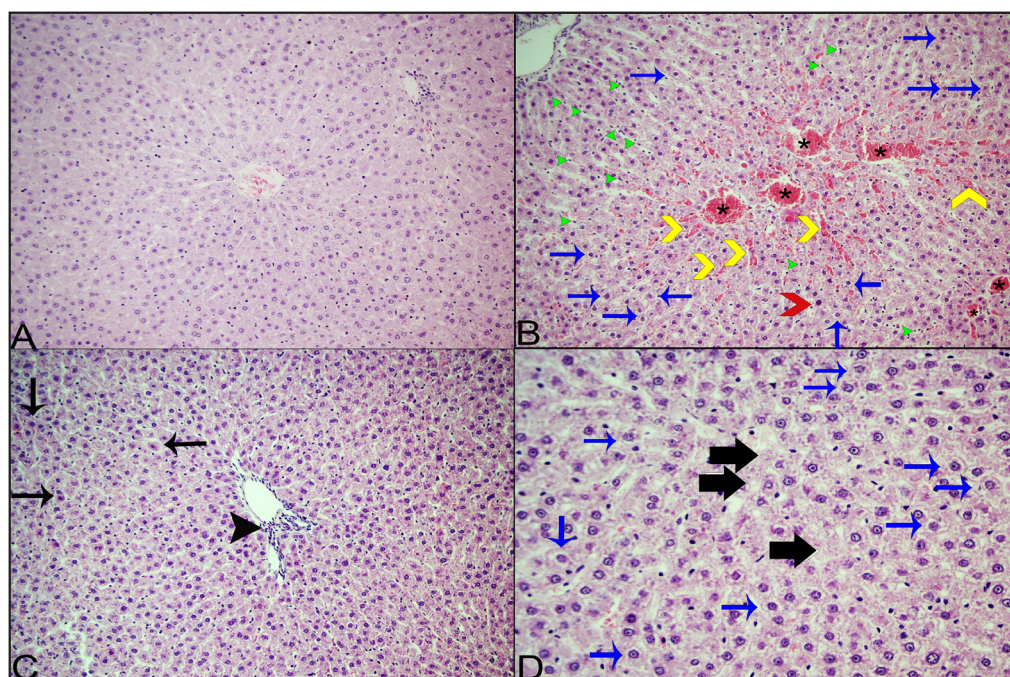


Figure 2. A. Control group. General view, X20, Hx E. B. AA group, X20, HXE. C. CRV group, X20, HXE. D. AA+CRV group, X40, HXE. Star: Congestion, Yellow arrowheads: Sinusoidal congestion, Blue arrows: Hydropic degeneration, Red arrowhead: Megalocytosis, Green arrowheads: Kupffer cells, Black arrows: necrotic/apoptotic cells. Black arrowhead: mononuclear cell infiltration.

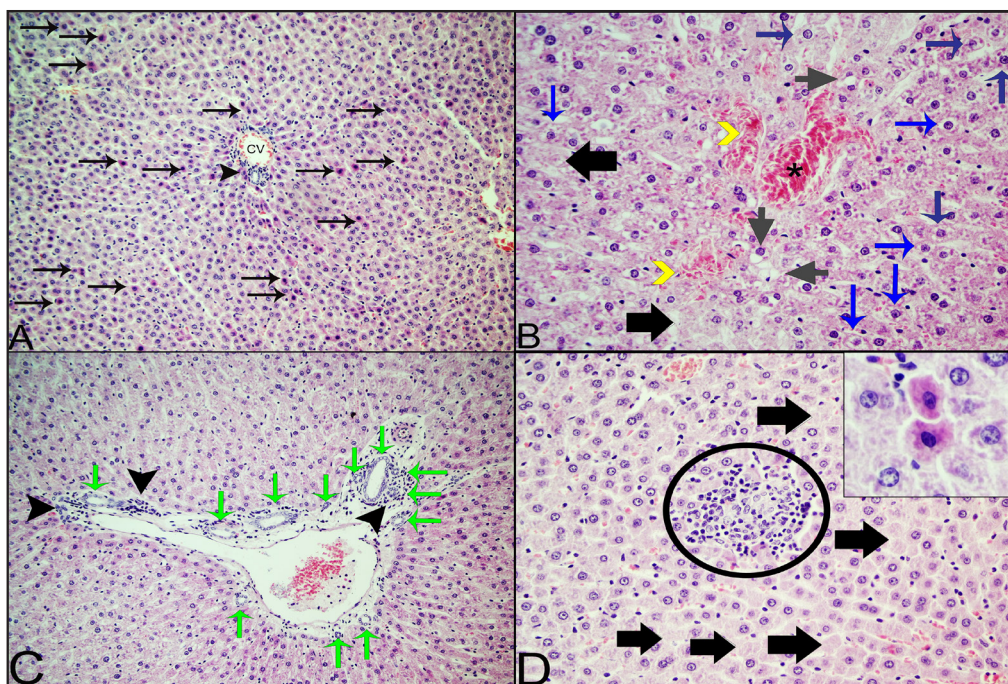


Figure 3. A-B-C-D; AA group, H&E. Objective Magnification: A,C: X20, B,D: X40. CV: Central ven; Star: Congestion; Yellow arrowheads: Sinusoidal congestion; Blue arrows: Hydropic degeneration; Gray arrows: steatosis; Green arrows: bile duct hyperplasia; Black arrows: necrotic/apoptotic cells; Black arrowhead: mononuclear cell infiltration; Black thick arrows: Single cell necrosis/apoptosis, Ring: focal mononuclear cell infiltration; Inset: Single cell necrosis/apoptosis (pale nucleus, eosinophilic cytoplasm).

score. These findings were also supported by significant improvement in liver function tests.

Conclusion

In conclusion, this study demonstrated that CRV mitigated AA-induced liver injury. The observed protective effect against liver toxicity is postulated to stem from CRV's antioxidant properties. Nevertheless, to precisely elucidate the molecular-level mechanism and provide applicable recommendations for clinical practice, additional comprehensive studies are warranted.

Conflict of Interest

The authors did not report any conflict of interest or financial support.

Funding

This study was supported by the Selcuk University Scientific Research Projects Coordination Office (Project Number: 22401136).

References

Abdel-Daim MM, Abo El-Ela FI, Alshahrani FK, Bin-Jumah M, et al., 2020. Protective effects of thymoquinone against acrylamide-induced liver, kidney and brain oxidative damage in rats. *Environ Sci Pollut Res*, 27, 37709-17.

Allam AA, El-Ghareeb AW, Abdul-Hamid M, Bakery AE, et al., 2010. Effect of prenatal and perinatal acrylamide on the biochemical and morphological changes in liver of developing albino rat. *Arch Toxicol*, 84, 129-41.

Al-Mosaibih MA, 2013. Effects of monosodium glutamate and acrylamide on the liver tissue of adult Wistar rats. *Life Sci*, 10, 2, 35-42.

Altinoz E, Turkoz Y, Vardi N, 2015. The protective effect of N-acetylcysteine against acrylamide toxicity in liver and small and large intestine tissues. *Bratisl Lek*, 116, 4, 252-258.

Alvarenga EM, Souza LK, Araújo TS, Nogueira KM, et al., 2016. Carvacrol reduces irinotecan-induced intestinal mucositis through inhibition of inflammation and oxidative damage via TRPA1 receptor activation. *Chem Biol Interact*, 260, 129-140.

Arusoglu G, 2015. Akrilamid oluşumu ve insan sağlığına etkileri. *Akademik Gıda*, 13, 1, 61-71.

Atasever A, Gram DY, Ekebas G, Onmaz NE, et al., 2020. Effect of fermented red radish (*Raphanus sativus* L) in carbon tetrachloride-induced liver injury in rats. *Thai J Vet Med*, 50, 405-416.

Ateş MB, Hatipoğlu D, 2022. Effect of nigella sativa oil on bisphenol a-induced hepatotoxicity in wistar albino rats: histopathological and biochemical investigation. *int j agric environ food sci*, 6, 3, 402-409.

Ates MB, Ozdemir O, Ozturk AE, Bucak MN, et al., 2022. Histopathological evaluation of the effects of thymoquinone and resveratrol on the liver in rats administered doxorubicin. *Eurasian J Vet Sci*, 38, 3, 150-158



- Banc R, Popa D-S, Cozma-Petruț A, Filip L, et al., 2022. Protective Effects of Wine Polyphenols on Oxidative Stress and Hepatotoxicity Induced by Acrylamide in Rats. *Antioxidants*, 11, 7, 1347.
- Baranauskaite J, Sadauskiene I, Liekis A, Kasauskas A, et al., 2020. Natural compounds rosmarinic acid and carvacrol counteract aluminium-induced oxidative stress. *Molecules*, 25, 8, 1807.
- Besaratinia A, Pfeifer GP, 2004. Genotoxicity of acrylamide and glycidamide. *J Natl Cancer Inst*, 96, 13, 1023-1029.
- Bin-Jumah MN, Al-Huqail AA, Abdelnaeim N, Kamel M, et al., 2021. Potential protective effects of *Spirulina platensis* on liver, kidney, and brain acrylamide toxicity in rats. *Environ Sci Pollut Res*, 28, 26653-26663.
- Boyacı CP, 2012. Determination of acrylamide exposure arising from the some baby foods used for toddler nutrition. Master's thesis, Akdeniz University, Institute of science and technology, Antalya.
- Bušová M, Bencko V, Laktičová KV, Holcátová I, et al., 2020. Risk of exposure to acrylamide. *Cent Eur J Public Health*, 28, 43-46.
- Center SA, 2007. Interpretation of liver enzymes. *Vet Clin North Am Small Anim*, 37, 2, 297-333.
- Erer H, Kiran M, Çiftçi M, 2009. *Veteriner Genel Patoloji*, 6. Edition, Bahçivanlar Basım Sanayi, Konya, pp; 108.
- Gedik S, Erdemli ME, Gul M, Yigitcan B, et al., 2017. Hepatoprotective effects of crocin on biochemical and histopathological alterations following acrylamide-induced liver injury in Wistar rats. *Biomed Pharmacother*, 95, 764-770.
- Ghonim A, 2023. Ameliorative effect of thymoquinone against acrylamide-induced hepatotoxicity in male rats. *Benha med j*, 43, 2, 31-35.
- Goorden S, Buffart TE, Bakker A, Buijs MM, 2013. Liver disorders in adults: ALT and AST. *Ned Tijdschr Geneesk*, 157, 43, A6443
- Greaves P, 2012. *Liver and pancreas. Histopathology of Preclinical Toxicity Studies*, 4th Edition, Elsevier Science, Amsterdam, Netherlands, pp; 433-535
- Gursul S, Karabulut I, Durmaz G, 2019. Antioxidant efficacy of thymol and carvacrol in microencapsulated walnut oil triacylglycerols. *Food Chem*, 278, 805-810.
- Gursul C, Ozcicek A, Ozkaraca M, Mendil AS, et al., 2022. Amelioration of oxidative damage parameters by carvacrol on methanol-induced liver injury in rats. *Exp Anim*, 71, 2, 224-230.
- Hatipoğlu D, Özsan M, Dönmez HH, Dönmez N, 2023. Hepatoprotective effects of nigella sativa oil against acrylamide-induced liver injury in rats. *Vet J Ankara Univ*, 70,4, 419-426.
- Iwakiri Y, 2015. Nitric oxide in liver fibrosis: The role of inducible nitric oxide synthase. *Clin Med Sci*, 21, 4, 319.
- Kantar FU, 2017. Karaciğer Fonksiyon Testi Yüksekliğine Yaklaşım. *Clin Med Sci*, 5, 2, 30-38.
- Kaplan MM, 1986. Serum alkaline phosphatase-another piece is added to the puzzle. *J Hepatol*, 6, 3, 526-528.
- Kim TH, Shin S, Kim KB, Seo WS, et al., 2015. Determination of acrylamide and glycidamide in various biological matrices by liquid chromatography-tandem mass spectrometry and its application to a pharmacokinetic study. *Talanta*, 131, 46-54.
- Kopanska M, Muchacka R, Czech J, Batoryna M, et al., 2018. Acrylamide toxicity and cholinergic nervous system. *J Physiol Pharmacol*, 69, 6, 847-858.
- Koszucka A, Nowak A, Nowak I, Motyl I, 2020. Acrylamide in human diet, its metabolism, toxicity, inactivation and the associated European Union legal regulations in food industry. *Crit Rev Food Sci Nutr*, 60, 10, 1677-1692.
- Kowalska M, Żbikowska A, Onacik-Gür S, Kowalska D, 2017. Acrylamide in food products-eating habits and consumer awareness among medical school students. *Ann Agric Environ Med*, 24, 4, 570-574
- Kwolek-Mirek M, Zdrażę-Tęcza R, Bednarska S, Bartosz G, 2011. Yeast *Saccharomyces cerevisiae* devoid of Cu, Zn-superoxide dismutase as a cellular model to study acrylamide toxicity. *In Vitro Toxicol*, 25, 2, 573-579.
- Lott JA, Wolf PL, 1986. Alanine and aspartate aminotransferase (ALT and AST). *Clinical enzymology: a case-oriented approach*. Chicago: Year Book Medical Publishers, pp; 111-138.
- Mahmood S, Amin K, Salih S, 2015. Effect of acrylamide on liver and kidneys in albino wistar rats. *Int J Curr Microbiol App Sci*, 4, 5, 434-444.
- Metin N, 1989. Farelerde Deneysel Lupinosis Ve İç Organlarda Şekillenen Morfalajik Değişiklikler. *Vet J Ankara Univ*, 36, 02, 496-502.
- Mojska H, Gielecińska I, Cendrowski A, 2016. Acrylamide content in cigarette mainstream smoke and estimation of exposure to acrylamide from tobacco smoke in Poland. *Ann Agric Environ Med*, 23, 3, 456-471
- Mollakhalili-Meybodi N, Khorshidian N, Nematollahi A, Arab M, 2021. Acrylamide in bread: a review on formation, health risk assessment, and determination by analytical techniques. *Environ Sci Pollut Res*, 28, 15627-15645.
- Moshtaghi AA, Javadi I, Feghhi G, 2003. Changes in the level of mitochondrial and cytosolic aspartate aminotransferase activities in aluminium intoxicated rat. *Iran Biomed J*, 7, 4, 167-171.
- Nan B, Yang C, Li L, Ye H, et al., 2021. Allicin alleviated acrylamide-induced NLRP3 inflammasome activation via oxidative stress and endoplasmic reticulum stress in Kupffer cells and SD rats liver. *Food Chem Toxicol*, 148, 111937.
- Öztürk İ, 2023. Therapeutic role of exogene melatonin on acrylamideinduced liver damage in rats with pinealectomy: effects on oxidative stress, inflammation and apoptosis. Doctoral thesis, Karabük University Institute of Graduate Programs Department of Medical Biochemistry, Karabük.
- Paulsson B, Rannug A, Henderson AP, Golding BT, et al., 2005. In vitro studies of the influence of glutathione transferases and epoxide hydrolase on the detoxification of acrylamide and glycidamide in blood. *Mutat Res Genet Toxicol Environ Mutagen*, 580, 1-2, 53- 59.
- Pekmez H, 2020. Siyah havuç suyu: Siçanlarda akrilamide bağlı hepatotoksititeyi tedavi etmede yeni bir yaklaşım. *Ank J Health Sci*, 207-216.
- Posta Ö, 2021. Akrilamid uygulanan HEPG2 hücrelerinde öjenolün hücre canlılığına, oksidatif strese ve ısı şok protein yanıtına etkisi, Master's Thesis, Trakya University Institute of Health Sciences.



- Powers SJ, Mottram DS, Curtis A, Halford NG, 2013. Acrylamide concentrations in potato crisps in Europe from 2002 to 2011. *Food Addit Contam: part A*, 30, 9, 1493-1500.
- Ranjini A, Manonmani H, 2019. Resveratrol protects acrylamide/glycidamide induced genotoxicity in hepatic cell line. *Pharm Innov J*, 8, 1, 56-64.
- Reitman S, Frankel S, 1957. A colorimetric method for the determination of serum glutamic oxalacetic and glutamic pyruvic transaminases. *Am J Clin Pathol*, 28, 1, 56-63.
- Rej R, 1989. Aminotransferases in disease. *Clin Lab Med*, 9, 4, 667-687.
- Sayed S, Alotaibi SS, El-Shehawi AM, Hassan MM, et al., 2022. The anti-inflammatory, anti-apoptotic, and antioxidant effects of a pomegranate-peel extract against acrylamide-induced hepatotoxicity in rats. *Life*, 12, 2, 224.
- Semla M, Goc Z, Martiniaková M, Omelka R, et al., 2017. Acrylamide: a common food toxin related to physiological functions and health. *Physiol Res*, 66, 2, 205.
- Sharifi-Rad M, Varoni EM, Iriti M, Martorell M, et al., 2018. Carvacrol and human health: A comprehensive review. *Phytother Res*, 32, 9, 1675-1687.
- Sinan İ, Acaröz U, Arslan-Acaröz D, Varol N, et al., 2018. Sıçanlarda akrilamid ile indüklenen oksidatif strese karşı taurinin koruyucu etkisi. *Kocatepe Vet. J*, 11, 4, 479-490.
- Sun R, Chen W, Cao X, Guo J, et al., 2020. Protective effect of curcumin on acrylamide-induced hepatic and renal impairment in rats: Involvement of CYP2E1. *Nat Prod Commun*, 15, 3, 1-9.
- Suntres ZE, Coccimiglio J, Alipour M, 2015. The bioactivity and toxicological actions of carvacrol. *Crit Rev Food Sci Nutr*, 55, 3, 304-318.
- Svensson K, Abramsson L, Becker W, Glynn A, et al, 2003. Dietary intake of acrylamide in Sweden. *Food Chem Toxicol*, 41, 11, 1581-1586.
- Teodor V, Cuciureanu M, Filip C, Zamosteanu N, et al., 2011. Protective effects of selenium on acrylamide toxicity in the liver of the rat. Effects on the oxidative stress. *Rev Med Chir Soc Med Nat Iasi*, 115, 2, 612-618.
- Tian X, Liu Y, Liu X, Gao S, et al., 2019. Glycyrrhizic acid ammonium salt alleviates Concanavalin A-induced immunological liver injury in mice through the regulation of the balance of immune cells and the inhibition of hepatocyte apoptosis. *Biomed Pharmacoter*, 120, 109481.
- Tohidi B, Rahimmalek M, Arzani A, Sabzalian MR, 2020. Thymol, carvacrol, and antioxidant accumulation in Thymus species in response to different light spectra emitted by light-emitting diodes. *Food chem*, 307, 125521.
- Tomaszewska E, Muszyński S, Świetlicka I, Wojtysiak D, Dobrowolski P, Arciszewski MB, Donaldson J, Czech A, Hułas-Stasiak M, Kuc D, 2022. Prenatal acrylamide exposure results in time-dependent changes in liver function and basal hematological, and oxidative parameters in weaned Wistar rats. *Sci Rep*, 12, 1, 14882.
- Wenk MR, & Fernandis AZ, 2007. A manual for biochemistry protocols. Volume 3, Jan-Thosten Shcantz, World Sci Res (World Scientific Publishing Co. Pte. Ltd), Singapore, pp; 70-75
- Wheeler MD, 2003. Endotoxin and Kupffer cell activation in alcoholic liver disease. *Alcohol Res Health*, 27, 4, 300.
- Yesildag K, Gur C, Ileriturk M, Kandemir FM, 2022. Evaluation of oxidative stress, inflammation, apoptosis, oxidative DNA damage and metalloproteinases in the lungs of rats treated with cadmium and carvacrol. *Mol Biol Rep*, 49, 1201-1211.
- Zhang L, Yang L, Luo Y, Dong L, et al., 2023. Acrylamide-Induced Hepatotoxicity Through Oxidative Stress: Mechanisms and Interventions. *Antioxid Redox Signal*, 38, 16, 1122-1137.
- Zhao M, Wang P, Zhu Y, Liu X, et al., 2015a. Blueberry anthocyanins extract inhibits acrylamide-induced diverse toxicity in mice by preventing oxidative stress and cytochrome P450 2E1 activation. *J Funct Foods*, 14, 95-101.
- Zhao M, Wang P, Zhu Y, Liu X, et al., 2015b. The chemoprotection of a blueberry anthocyanin extract against the acrylamide-induced oxidative stress in mitochondria: unequivocal evidence in mice liver. *Food funct*, 6, 9, 3006-3012.
- Zhao S, Sun H, Liu Q, Shen Y, et al., 2020. Protective effect of seabuckthorn berry juice against acrylamide-induced oxidative damage in rats. *J Food Sci*, 85, 7, 2245-2254.

Author Contributions

Motivation/Concept: MBA, DH; Design: MBA, DH; Control/Supervision: MBA, DH; Data Collection and/or Processing: AB, GS; Analysis and/or Interpretation: MBA, DH, AB; Literature Review: AB; Writing the Article: AB; Critical Review: MBA, DH.

Ethical Approval

Selcuk University Experimental Research and Application Center Animal Experiments Ethics Committee approved with Ethics Committee Decision Number 2019-59.