



RESEARCH ARTICLE

Potential therapeutic effect of Thymoquinone on Cisplatin-induced hepatotoxicity in rats

Sercan Kaya*, Tuba Yalcin

Batman University, Vocational School of Healthcare Studies, Batman, Türkiye

Received: 31.10.2023 , Accepted: 14.02.2024

*sercan.kaya@batman.edu.tr

Timokinonun sıçanlarda Sisplatin kaynaklı hepatotoksisite üzerindeki potansiyel terapötik etkisi

Eurasian J Vet Sci, 2024, 40, 1, 1-9

DOI: 10.15312/EurasianJVetSci.2024.419

Öz

Amaç: Antineoplastik bir ajan olan Sisplatin (CIS), hepatotoksisite gibi ciddi yan etkiler gösterir. Timokinon (ThQ), anti-inflamatuar, anti-tümöral gibi birçok faydalı etkiye sahip güçlü bir anti-oksidandır. Bu çalışmanın amacı, sıçanlarda CIS kaynaklı hepatotoksisite modelinde ThQ tedavisinin hepatoprotektif etkisinin olup olmadığını incelemesi ve ayrıca CIS ve\veya ThQ uygulamalarının karaciğer dokusunda, deubikuitinazlardan biri olan OTULIN düzeylerini nasıl etkilediğinin belirlenmesidir.

Gereç ve Yöntem: Çalışmada kullanılan 28 adet rat; kontrol (uygulama yok), CIS (7 mg/kg CIS, deneyin ilk günü, intraperitoneal), CIS+ThQ (7 mg/kg CIS, deneyin ilk günü, intraperitoneal + 10 mg/kg/gün ThQ, oral gavaj) ve ThQ (10 mg/kg/gün ThQ, oral gavaj) olmak üzere eşit sayıda dört gruba ayrıldı (n=7). Tüm uygulamaların tamamlanmasıyla (15. gün) deney sonlandırıldı. CIS ve\veya ThQ uygulamalarının karaciğer dokusu üzerindeki etkileri biyokimyasal, histopatolojik ve immünohistokimyasal olarak incelendi.

Bulgular: CIS uygulaması karaciğer dokusunda karaciğer enzim düzeylerini, histopatolojik değişiklikleri, oksidatif stresi, inflamasyonu ve apoptozu artırırken OTULIN düzeyinin azalmasına neden olmuştur. Bununla birlikte ThQ uygulaması, karaciğer dokusunda CIS kaynaklı oluşan değişiklikleri olumlu yönde düzenleyici etki göstermiştir.

Öneri: ThQ takviyesi CIS kaynaklı karaciğer dokusu hasarına karşı hepatoprotektif etkiye sahiptir.

Anahtar kelimeler: Hepatotoksisite, otulin, sisplatin, timokinon.

Abstract

Aim: Cisplatin (CIS), an antineoplastic agent, shows serious side effects such as hepatotoxicity. Thymoquinone (ThQ) is a powerful anti-oxidant with many beneficial effects such as anti-inflammatory, anti-tumoral. The aim of this study was to investigate whether ThQ treatment has hepatoprotective effect in CIS-induced hepatotoxicity model in rats and also to determine how CIS and/or ThQ treatments affect OTULIN levels, one of the deubiquitinases, in liver tissue.

Materials and Methods: The 28 rats used in the study control (application not done), CIS (7 mg/kg CIS, first day of experiment, intraperitoneal), CIS+ThQ (7 mg/kg CIS, first day of experiment, intraperitoneal + 10 mg/kg/day ThQ, oral gavage) and ThQ (10 mg/kg/day ThQ, oral gavage) were divided into four equal groups (n=7). The experiment was terminated upon completion of all applications (day 15). The effects of CIS and/or ThQ apps on liver tissues were examined biochemically, histopathologically and immunohistochemically.

Results: CIS application increased liver enzyme levels, histopathological changes, inflammation, oxidative stress and apoptosis in liver tissue and caused a decrease in OTULIN level. However, ThQ administration showed a positive regulatory effect on CIS-induced changes in liver tissue..

Conclusion: ThQ supplementation has a hepatoprotective effect against CIS-induced liver tissue damage.

Keywords: Hepatotoksisite, otulin, cisplatin, thymoquinone.

CITE THIS ARTICLE: Kaya and Yalcin 2024. Potential therapeutic effect of Thymoquinone on Cisplatin-induced hepatotoxicity in rats Eurasian J Vet Sci, 40, 1, 1-9



Introduction

Cisplatin (CIS), an antineoplastic medicine, is used to treat cancer (Abd Rashid et al 2021). However, CIS also has serious toxic effects on various tissues such as the liver, kidney, and heart (Hu et al 2018, Eid and El-Shitany 2021, Zhang et al 2022). The liver is central to metabolic reactions. After CIS infusion, it rapidly diffuses into various tissues and reaches high concentrations in the liver (Quintanilha et al 2017). In CIS-induced hepatotoxicity, excessive production of reactive oxygen radicals (ROS), DNA damage, inflammation, and apoptosis are the focus (Abd Rashid et al 2021). Excessive production of ROS triggers oxidative stress, causing damage to biomolecules (Basaran et al 2022). When drugs cause liver damage, inflammation and oxidative stress are major factors. Therefore, considering the critical role played by inflammatory reactions and oxidative stress in CIS-induced hepatotoxicity, it suggests that a treatment strategy that can overcome this condition should be aimed at attenuating them (Ramadan et al 2023). However, although increased inflammation and oxidative stress are the main mechanisms involved in CIS-induced toxicity, other molecular pathways and detailed mechanisms still remain unclear (Fathy et al 2022).

Antioxidants, which reduce oxidative damage and ROS-induced negative effects on cells, show cytoprotective properties (Cakmak et al 2022). One of them, *Nigella sativa*, is a member of the Ranunculaceae family and is grown and used as a medicinal plant in many Asian and African countries (Oz et al 2023). It has recently been reported that Acrylamide intoxication causes lipid peroxidation, oxidative stress, and liver damage through a serious inflammatory response, but *Nigella sativa* essential oil application has a hepatoprotective effect against Acrylamide-induced negativities (Hatipoglu et al 2023). It has also been shown that *Nigella sativa* oil has a protective effect against deteriorations in liver enzymes, carbohydrate metabolism, and oxidative parameters due to CIS application in rats (Farooqui et al 2016). However, the main bioactive compound of *Nigella sativa* is Thymoquinone (ThQ). Many studies have confirmed that ThQ has a strong antioxidant and anti-inflammatory effect (Shahid et al 2021, Yalcin and Kaya 2023a).

To our knowledge, it has not been previously investigated how ThQ treatment affects the levels of OTULIN, a deubiquitinase known to participate in inflammatory reactions (Yalcin et al 2023), in liver tissue on CIS-induced hepatotoxicity in rats. The aim of this research is to detect whether ThQ treatment shows anti-inflammatory, anti-oxidant, and anti-apoptotic effects in CIS-induced hepatotoxicity and how it affects OTULIN levels in liver tissue in this process.

Material and Methods

Experimental approach

This study was started with the confirmation of the Dicle University Animal Experiments Local Ethics Committee, dated 29/03/2022-259525. To be used in the experimental design, ThQ (1:1 mg/ml, Cayman, USA) and CIS (50:100 mg/ml, Koçak, Turkey) were purchased from companies. Rats were housed under standard care conditions ($23\pm 2^{\circ}\text{C}$, ad libitum water and food, 12h light-dark cycle). The 28 rats (8-10 weeks old, Sprague-Dawley, male, 230 ± 20 g) were randomly divided into four different groups: Control (n=7): No treatment was applied. CIS (n=7): On day one of the study, an intraperitoneal injection of 7 mg/kg CIS was given. CIS+ThQ (n=7): On day one of the study 7 mg/kg CIS was applied intraperitoneally and 10 mg/kg ThQ was applied by oral gavage throughout the experiment. ThQ (n=7): 10 mg/kg ThQ was applied by oral gavage throughout the experiment. The CIS and ThQ doses determined in the experimental design were referenced from the studies performed (Hagar et al 2019, Danaei et al 2022). Upon completion of all applications (day 15), the rats were dissected accompanied by anesthesia (xylazine 10 mg/kg - ketamine 75 mg/kg) after intracardiac bloods were taken (yellow cap biochemistry tube containing separator gel). A portion of the rapidly taken liver tissues was fixed using 10% formalin for histological and histopathological examinations. Serum obtained from blood samples and remaining liver tissues were preserved at -80°C .

Biochemical analysis

To detect liver enzyme levels, blood serums stored at -80°C were solved once after the experiment. Serum Aspartate aminotransferase (AST) and Alanine aminotransferase (ALT) levels were detected using an automatic autoanalyzer (2400-ADVIA, Siemens) device.

Supernatants were obtained by homogenizing liver tissues ($+4^{\circ}\text{C}$, 10% phosphate buffer solution, 20 min, 5000 rpm). These supernatants were studied with enzyme-linked immunosorbent assays (ELISA), and Interleukin 6 (IL6) and Malondialdehyde (MDA) levels were determined in liver tissue. ELISA kits, IL6 (ELK1158, Wuhan, China) and MDA (ELK8612, Wuhan, China), obtained from commercial companies were studied in accordance with the manufacturer's instructions. IL6 and MDA concentrations were calculated by plotting the optical value and concentration graph obtained by measuring the microplates spectrophotometrically at a wavelength of 450 nm. MDA: sensitivity; 5.39 pg/ml, test range; 15.63- 1000 pg/ml. IL6: sensitivity; 3.3 pg/ml, test range; 7.82- 500 pg/ml (Chen et al 2019).



Histopathological examination

After liver tissues were fixed in 10% formalin, they were subjected to a histological follow-up series. Hematoxylin Eosin was used to stain liver tissue sections for general histological and histopathological evaluations. The prepared liver tissue preparations were reviewed under a light microscope and photographed (Leica/DM2500, Germany). In histopathological evaluation of liver tissues; hepatocyte degeneration, sinusoidal dilatation, vacuolization, and the presence of inflammation foci are the criteria used. Taking into account the presence of histopathological criteria, a histopathological histoscore table was created (none=0, mild=1, moderate=2, severe=3) (Kaya et al 2023a).

Immunohistochemical evaluation

In liver tissues, B cell lymphoma 2 (Bcl2) (1:200, 201r.5304, SunRed, China), Bcl2 associated X (BaX) (1:100, sc7480, Santa Cruz, USA), Caspase 3 (Casp 3) (1:200, Bioss, bs0081R, China), OTULIN (1:200, A07938-1, Boster, CA), Tumor Necrosis Factor α (TNF- α) (1:100, BL3376, Elabscience, USA), Interleukin (IL-1 β) (1:200, sc1251, Santa Cruz, USA), immunoreactivities were detected using the Avidin-Biotin-Peroxidase-Complex method. Incubation time was 60 min (37°C) for primary antibodies and 30 min (37°C) for secondary antibodies (TP-060-BN, Thermo Sci., England). 3-amino-9-ethyl carbazole (AEC) (TA-060-HA, Thermo Sci., England) was used as chromogen. Mayer hematoxylin was used for counterstaining of all sections. The liver tissue sections were reviewed under a light microscope and photographed (DM2500/Leica, Germany). The immunoreactivity was calculated using the "prevalence X severity" formula (Kaya et al 2023b).

Statistical analyses

Statistical analyses of the research data were performed using the SPSS 22.0 (IBM Corp., Armonk, New York, USA) package program. The Shapiro-Wilk test was used to check whether the data were normally distributed. A one-way analysis of variance (ANOVA) test was used to determine the differences between normally distributed parameters, and the TUKEY test, one of the post-hoc tests, was used to determine from which group the difference originated. The Kruskal-Wallis test was used to determine the differences between parameters that did not show a normal distribution, and the Mann-Whitney U test was used for pairwise comparisons. P values less than 0.05 were regarded as statistically significant. Study data were presented in graphs drawn using Graph Pad Prism 9.3.1 software.

Results

Serum liver enzymes and liver tissue MDA levels

Serum AST and ALT levels, which are frequently used as liver damage biomarkers, were at similar levels in the control and ThQ groups ($p > 0.05$). Increased liver enzyme levels were detected in the CIS group compared to the control group ($p < 0.05$). When the CIS+ThQ group was compared with the CIS group, it was detected that there was a decrease in serum ALT and AST values ($p < 0.05$) (Figure 1).

There was no difference between MDA levels in the control and ThQ groups ($p > 0.05$). However, it was observed that MDA levels increased in the CIS group compared with the control group ($p < 0.05$). On the other hand, when the CIS+ThQ group was compared with the CIS group, MDA levels were determined to decrease ($p < 0.05$) (Figure 1).

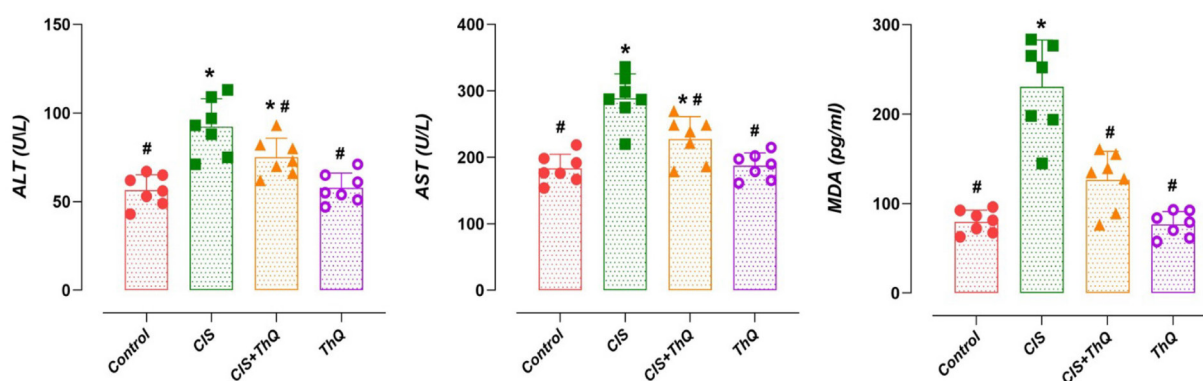


Figure 1. Effect of CIS and/or ThQ applications on liver enzyme levels in serum and MDA levels in liver. ALT, AST and MDA levels were similar in the control and ThQ groups ($p > 0.05$). ALT, AST and MDA levels increased in the CIS group compared to the control group ($p < 0.05$). ALT, AST and MDA levels decreased in the CIS+ThQ group compared to the CIS group ($p < 0.05$). *, compared to the control group ($p < 0.05$), #, compared with the CIS group ($p < 0.05$). CIS; Cisplatin, ThQ; Thymoquinone, ALT; Alanine aminotransferase, AST; Aspartate Aminotransferase, MDA; Malondialdehyde.



Table 1. Effect of CIS and/or ThQ applications on liver histopathology: Histopathological histoscore table

	Control	CIS	CIS+ThQ	ThQ	p
Sinusoidal dilatation	0.10±0.08	2.31±0.23 ^a	1.08±0.21 ^{a b}	0.08±0.06 ^b	<0.001
Hematopoietic foci	0.17±0.11	2.28±0.24 ^a	0.92±0.30 ^b	0.12±0.11 ^b	<0.001
Intracytoplasmic vacuolization	0.17±0.09	2.02±0.24 ^a	0.91±0.19 ^{a b}	0.20±0.11 ^b	<0.001

Data are presented as mean±standard deviation. p ANOVA post-hoc Tukey. a; compared to the control group (p<0.05), b; compared with the CIS group (p<0.05). CIS; Cisplatin, ThQ; Thymoquinone.

Liver histopathology

In the histopathological investigation of liver tissues, liver tissues in the control and ThQ groups had a normal histological structure. In the CIS group, intracytoplasmic vacuolization, sinusoidal dilation, and the presence of hematopoietic foci were noteworthy. Histopathological alterations were found to be rare or lighter in the CIS+ThQ group as compared to the CIS group (p <0.05) (Table 1, Figure 2).

Inflammatory markers and OTULIN levels

There were no differences between inflammatory markers and OTULIN immunoreactivities in the liver tissues of the control and ThQ groups (p >0.05). Liver IL6 ELISA levels, TNF- α and IL-1 β immunoreactivities were augmented in the CIS group compared with the control group (p <0.05). In the CIS+ThQ group, liver IL6 ELISA levels, TNF- α and IL-1 β immunoreactivities were diminished compared with the CIS group (p <0.05) (Figure 3). It was observed that OTULIN

immunoreactivity in the liver was lower in the CIS group compared to the control group (p <0.05). Increased OTULIN immunoreactivity was determined in the CIS+ThQ group compared to the CIS group (p <0.05) (Figure 3).

Apoptotic markers

There was no difference between the immunoreactivities of apoptotic markers in the liver tissues of the control and ThQ groups (p >0.05). While Bcl2 immunoreactivities diminished in the liver tissues in the CIS group compared to the control group, Bax and Casp3 immunoreactivities increased (p <0.05). It was also detected that the Bax/Bcl2 ratio increased in the CIS group compared to the control group (p <0.05). While Bcl2 immunoreactivity increased in the CIS+ThQ group compared to the CIS group, Bax and Casp3 immunoreactivities decreased (p <0.05). It was detected that the Bax/Bcl2 ratio was also diminished in the CIS+ThQ group compared with the CIS group (p <0.05) (Figure 4).

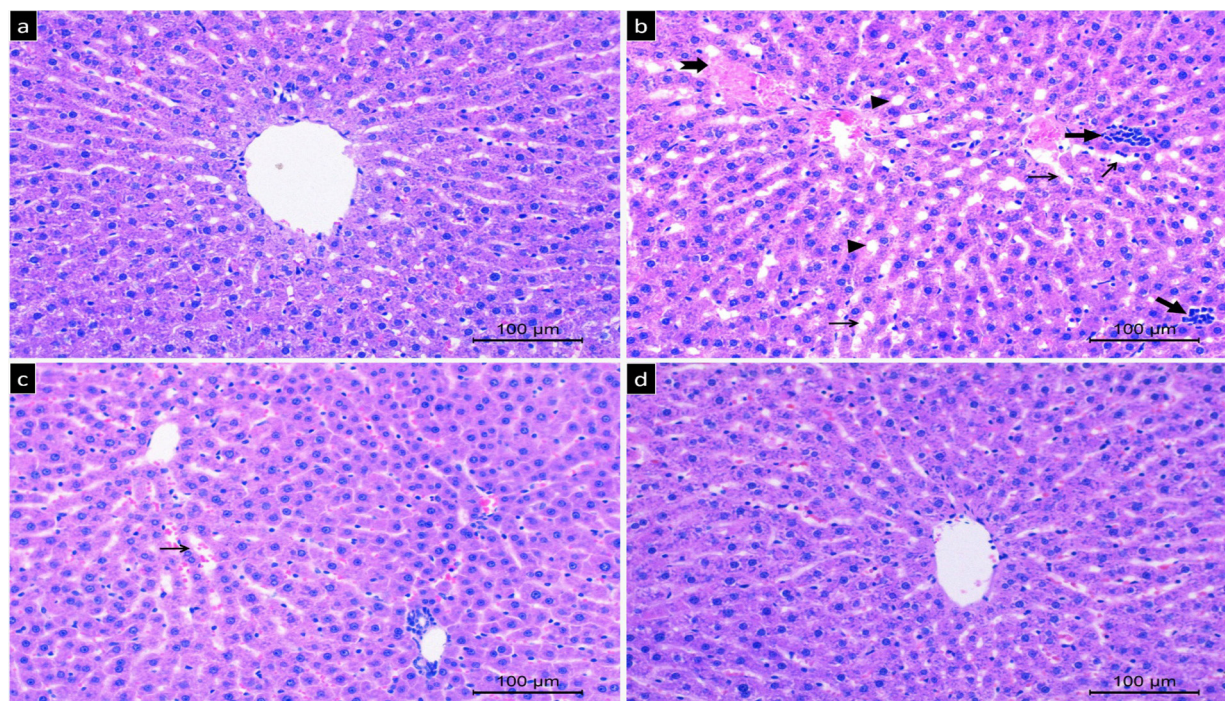


Figure 2. Photomicrographs of the effect of CIS and/or ThQ applications on liver histopathology. Liver tissue in the control and ThQ groups had a normal histological structure. Diffuse histopathological changes were observed in the CIS group compared to the control group (p<0.05). It was noteworthy that the histopathological changes were significantly reduced in the CIS+ThQ group compared to the CIS group (p<0.05). Hematoxylin Eosin, x20 magnification, scale bar; 100µm. Groups, a; control, b; CIS, c; CIS+ThQ, d;ThQ. Thin arrow; sinusoidal dilatation, thick arrow; foci of inflammation, notched arrow; degenerated hepatocytes, triangle; vacuolization. CIS; Cisplatin, ThQ; Thymoquinone.

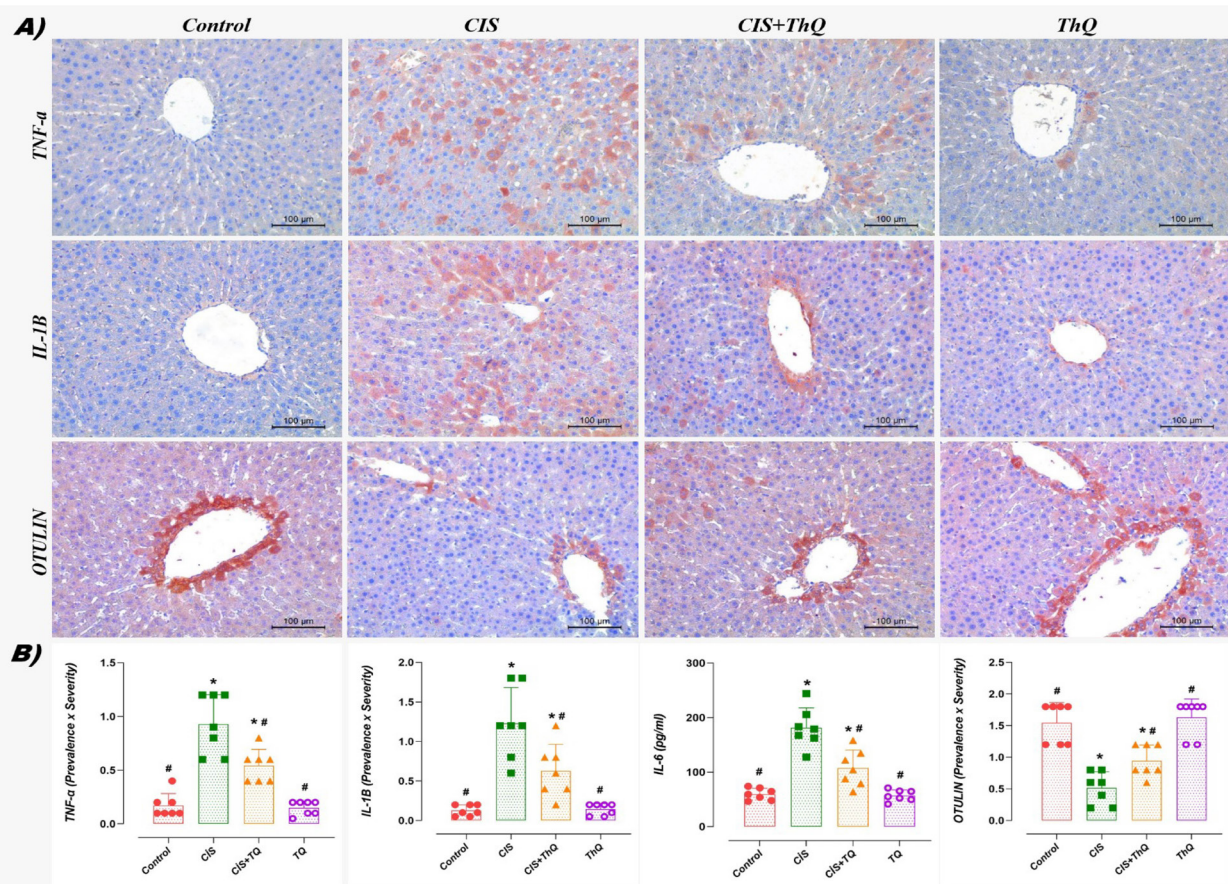


Figure 3. Effect of CIS and/or ThQ applications on inflammatory markers and OTULIN levels in liver tissue; A) Photomicrographic B) Graphic. Inflammatory markers and OTULIN immunoreactivities were similar in the control and ThQ groups ($p > 0.05$). In the CIS group, IL-6, TNF- α and IL-1 β levels increased in liver tissue compared to the control group, while OTULIN immunoreactivities decreased ($p < 0.05$). It was observed that OTULIN immunoreactivities increased while IL-6, TNF- α and IL-1 β levels decreased in the CIS+ThQ group compared to the CIS group ($p < 0.05$). A) TNF- α , IL-1 β and OTULIN immunohistochemical staining, x20 magnification, scale bar; 100 μ m. B) *: compared to the control group ($p < 0.05$), #: compared with the CIS group ($p < 0.05$). CIS; Cisplatin, ThQ; Thymoquinone. IL-1 β ; Interleukin-1 β , IL-6; Interleukin-6, TNF- α ; Tumor Necrosis Factor Alpha.

Discussion

CIS is a powerful anticancer drug, but it causes hepatotoxicity in addition to its therapeutic effects (Al-Malki and Sayed 2014). Many pharmacological and therapeutic characteristics, such as anti-inflammatory, antioxidant, anticancer, and hepatoprotective effects, are displayed by ThQ. With this study, we present a report showing that ThQ treatment has a hepatoprotective effect in the CIS-induced hepatotoxic rat model by regulating inflammation, apoptosis, oxidative and OTULIN immunoreactivity in liver tissues.

An endogenous chain reaction known as lipid peroxidation causes lipids to break down oxidatively and produces a variety of oxidation products (Kaya and Yalcin 2023). MDA, the end product of lipid peroxidation, is often used as a marker indicating oxidative stress (Gianazza et al 2019). A recent study reported that the level of MDA, one of the oxidative stress parameters, increased in the liver after CIS treatment (Akdemir et al 2022). This study showed that MDA levels increased after CIS treatment. These findings were consistent with prior research showing an increase in MDA levels and oxidative damage caused by CIS (Aboraya et al 2022).

The reason why liver enzyme levels increase in circulation is the disruption of cell membrane integrity in hepatocytes in response to the negative effects of some drugs and pathological conditions. Serum ALT and AST levels are very important in the evaluation of liver damage. Because the cytoplasm contains these enzymes, which start to circulate more when liver tissue is damaged. A study reported that liver enzyme levels increased after CIS treatment (Aboraya et al 2022). In similar lines, this study found that CIS significantly raised ALT and AST levels. In parallel with these results, other studies reported increased ALT and AST values in CIS-induced hepatotoxicity (Niazvand et al 2023). However, in a study, it was reported that ThQ, which has a strong antioxidant effect, reduced the increased ALT and AST levels in the liver tissue caused by arsenic and suppressed oxidative stress (Alam et al 2022). In similar lines, the present investigation found that ThQ supplementation decreased the raised MDA and liver enzyme levels caused by CIS.

Indeed, the results achieved in this study revealed hepatic impairment as demonstrated by the increase in markers of hepatic function such as serum ALT and AST levels, which are frequently used to evaluate chemical/drug-induced hepatotoxicity. Additionally, these results were supported

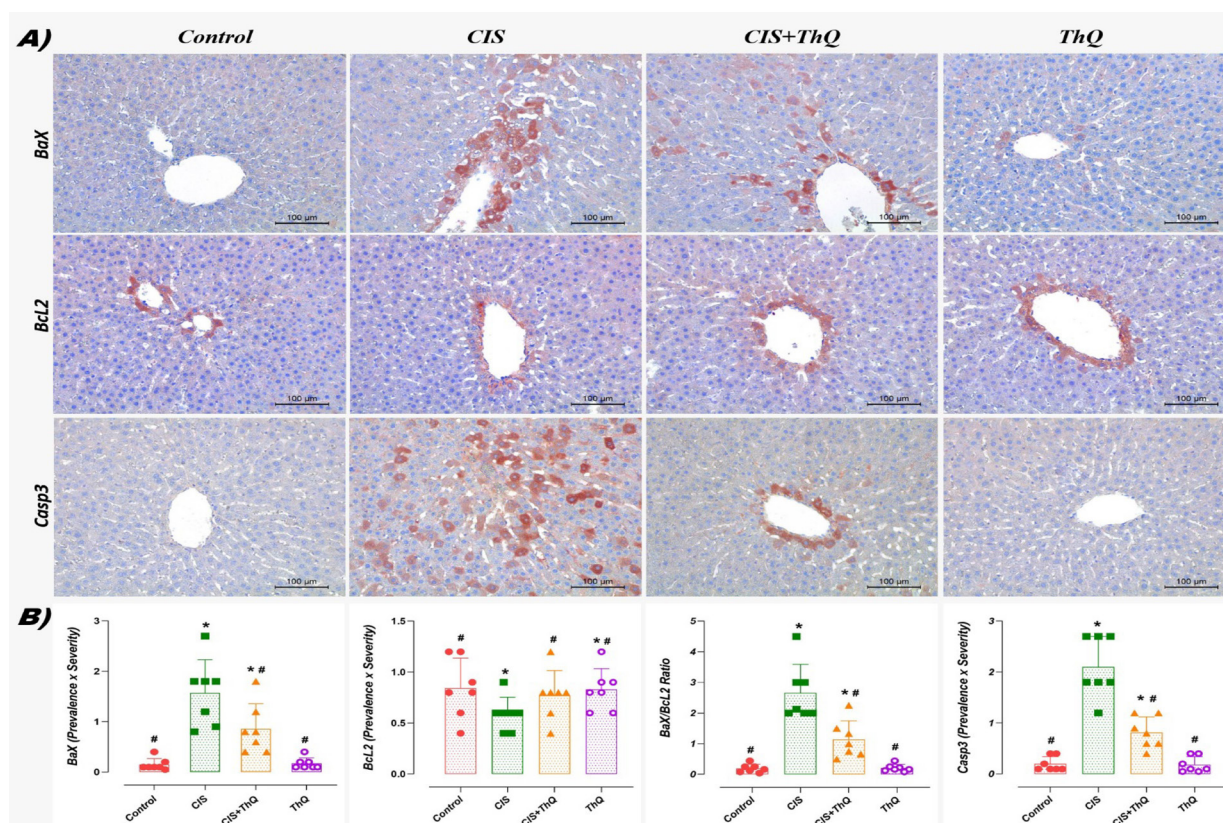


Figure 4. Effect of CIS and/or ThQ applications on apoptotic markers in liver tissue; A) Photomicrographic B) Graphic. Apoptotic markers were at similar levels in the control and ThQ groups ($p > 0.05$). While Bcl2 immunoreactivity decreased in the CIS group compared to the control group, BaX/Bcl2 ratio, BaX and Casp3 immunoreactivities increased ($p < 0.05$). While Bcl2 immunoreactivity increased in the CIS+ThQ group compared to the CIS group, BaX/Bcl2 ratio, BaX and Casp3 immunoreactivities decreased ($p < 0.05$). A) BaX, Bcl2, and Casp3 immunohistochemical staining, x20 magnification, scale bar; 100 μm. B) *; compared to the control group ($p < 0.05$), #; compared with the CIS group ($p < 0.05$). CIS; Cisplatin, ThQ; Thymoquinone.

by liver histopathology, which showed widespread tissue damage such as intracytoplasmic vacuolization, hematopoietic foci, and sinusoidal dilatation in CIS-treated rats. Consistent with these data, a study reported that even low-dose CIS administration caused hepatotoxicity. The same study reported that CIS treatment caused including disorganized hepatic cords, massive hepatic toxicity, necrosis, and focal inflammatory lesions (Singh et al 2015). Similarly, another recent study showed that CIS application caused serious histopathological changes in liver tissue (Alkhalaf et al 2023). However, a study reported that histopathological changes in liver tissue caused by CIS were alleviated by ThQ supplementation (Shahid et al 2021). The results obtained in this current study, which was conducted in parallel with this study, showed that ThQ application was very effective in reducing the histopathological changes that occur in CIS-induced hepatotoxicity.

Excessive accumulation of ROS in cells is directly related to the secretion of pro-inflammatory cytokines through some pro-apoptotic cellular pathways and NF-κB (Sadhukhan et al 2018). Additionally, inflammation may occur as a complication of oxidative stress. In a study, it was reported that pro-inflammatory cytokines increased in CIS-induced hepatotoxicity (Aboraya et al 2022). The present

investigation revealed a significant increase in TNF-α, IL6, and IL-1β levels in liver tissue upon CIS application. Consistent with these findings, other research revealed that the application of CIS raised the levels of cytokines that were associated with inflammation (Bilgic et al 2018). On the other hand, this study determined that ThQ supplementation was effective in reducing the increased levels of TNF-α, IL6, and IL-1β caused by CIS. Likewise, ThQ has been demonstrated in a study to have an anti-inflammatory effect by lowering pro-inflammatory cytokines like TNF-α and IL-1β, which rise in response to CIS (Al-Malki and Sayed 2014). OTULIN is an endogenous regulator involved in the regulation of inflammatory responses. Through NF-κB, OTULIN actively regulates inflammatory processes (Aksentijevich and Zhou 2017). OTULIN levels have been shown to drop in an experimental myocardial infarction model and to negatively correlate with pro-inflammatory cytokines like TNF-α (Kaya and Yalcin 2023). Another study reported that OTULIN was reduced in nephrotoxicity caused by the anticancer drug Doxorubicin (Yalcin et al 2023). In similar lines, this study found that CIS-induced hepatotoxicity caused a decline in OTULIN immunoreactivity in liver tissue. On the other hand, it has been shown that overexpression of OTULIN inhibits the NF-κB pathway, which in turn prevents excessive activation of microglial cells and the production of pro-



inflammatory cytokines. This resulted in the regulation of neurological functions and the reduction of neuron death (Xu et al 2018). In the present investigation, it was found that ThQ supplementation markedly raised OTULIN immunoreactivity, which had been considerably reduced by CIS in liver tissue. In addition, it has been reported that increased pro-inflammatory cytokines and ROS production cause apoptosis in hepatocytes (Aboraya et al 2022).

Apoptosis is a complex process in which various protein structures and signaling pathways in cells participate. Pro-apoptotic and anti-apoptotic proteins are the two types of proteins involved in apoptosis. Bcl2 family proteins located in the mitochondrial outer membrane play both anti-apoptotic (Bcl2, etc.) and pro-apoptotic (Bax, etc.) roles (Yalcin and Kaya 2023b). However, reducing ROS production in cells is very important for preserving the functions of mitochondria, which are the primary source of free radicals (Sahin et al 2023). When cellular damage becomes irreversible, the caspase-dependent apoptotic pathway is activated by altering the Bax/Bcl2 ratio, which is mediated by mitochondrial dysfunction, and apoptosis is initiated by suppressing Bcl2 anti-apoptotic (Abd Rashid et al 2021). According to a study, CIS treatment significantly increased the expression of Bax and Casp3 in the liver (Aboraya et al 2022). In this study, CIS application increased Bax and Casp3 immunoreactivities in liver tissues. These findings were in line with earlier research that demonstrated the involvement of apoptosis in CIS-induced hepatotoxicity (Neamatallah et al 2018, Hassan et al 2020). Nonetheless, the current study's findings regarding the CIS application's reduction in Bcl2 levels in liver tissues were in line with earlier research (Hassan et al 2020, Niazvand et al 2023). On the other hand, in this study, it was found that CIS-induced altered apoptotic markers were significantly regulated by ThQ treatment. Similarly, a previous study reported that ThQ showed an antiapoptotic effect by increasing the level of antiapoptotic Bcl2 in addition to normalizing the level of proapoptotic Bax in the hepatocytes (Awad et al 2016). The current study's limitation is that it did not evaluate the potential of ThQ supplementation on the anti-cancer effect of CIS treatment, despite the fact that it offers strong evidence for the anti-oxidant, anti-inflammatory, and anti-apoptotic potential of ThQ supplementation in CIS-induced hepatotoxicity.

Conclusion

As a result, in this study, it was detected that CIS application caused hepatotoxicity in liver tissue, especially through oxidative stress and inflammation. Additionally, a decrease in OTULIN immunoreactivity was detected in CIS-induced hepatotoxicity, possibly related to inflammation. However, it was detected that ThQ treatment showed anti-oxidant, anti-apoptotic, anti-inflammatory, and OTULIN

these results are achieved.

Acknowledgements

A part of this study was presented as an oral presentation at the 5th International Congress of Multidisciplinary Studies in Medical Sciences and was published as an abstract text in the congress book.

Conflict of Interest

The authors did not report any conflict of interest or financial support.

Funding

This research received no grant from any funding agency/sector.

References

- Abd Rashid N, Abd Halim SAS, Teoh SL, Budin SB, et al., 2021. The role of natural antioxidants in cisplatin-induced hepatotoxicity. *Biomed Pharmacother*, 144, 112328. <https://doi.org/10.1016/j.biopha.2021.112328>.
- Aboraya DM, El Baz A, Risha EF, Abdelhamid FM, 2022. Hesperidin ameliorates cisplatin induced hepatotoxicity and attenuates oxidative damage, cell apoptosis, and inflammation in rats. *Saudi J Biol Sci*, 29(5), 3157-3166. <https://doi.org/10.1016/j.sjbs.2022.01.052>.
- Akdemir FNE, Yildirim S, Kandemir FM, 2022. The possible beneficial impacts of evodiamine on hepatotoxicity induced by cisplatin. *Environ Sci Pollut Res Int*, 29(59), 89522-89529. <https://doi.org/10.1007/s11356-022-22007-x>.
- Aksentijevich I, Zhou Q, 2017. NF- κ B pathway in autoinflammatory diseases: dysregulation of protein modifications by ubiquitin defines a new category of autoinflammatory diseases. *Front Immunol*, 8, 399. <https://doi.org/10.3389/fimmu.2017.00399>.
- Alam T, Shahid F, Abidi S, Parwez I, et al., 2022. Thymoquinone supplementation mitigates arsenic-induced cytotoxic and genotoxic alterations in rat liver. *J Trace Elem Med Biol*, 74, 127067. <https://doi.org/10.1016/j.jtemb.2022.127067>.
- Alkhalaf M, Mohamed NA, El-Toukhy SE, 2023. Prophylactic consequences of sodium salicylate nanoparticles in cisplatin-mediated hepatotoxicity. *Sci Rep*, 13(1), 10045. <https://doi.org/10.1038/s41598-023-35916-9>.
- Al-Malki AL, Sayed AAR, 2014. Thymoquinone attenuates cisplatin-induced hepatotoxicity via nuclear factor kappa- β . *BMC Complement Altern Med*, 14, 282. <https://doi.org/10.1186/1472-6882-14-282>.
- Awad AS, Abd Al Haleem EN, El-Bakly WM Sherief MA, 2016. Thymoquinone alleviates nonalcoholic fatty liver disease in rats via suppression of oxidative stress, inflammation, apoptosis. *Naunyn Schmiedeberg's Arch Pharmacol*, 389,



- 381–391. <https://doi.org/10.1007/s00210-015-1207-1>.
- Basaran E, Hasimi N, Cakmak R, Cinar E, 2022. Synthesis, structural characterization, and biological evaluation of some hydrazone compounds as potential antioxidant agents. *Russ J Bioorg Chem*, 48(1), 143-152. <https://doi.org/10.1134/S1068162022010058>.
- Bilgic Y, Akbulut S, Aksungur Z, Erdemli ME, et al., 2018. Protective effect of dexpanthenol against cisplatin induced hepatotoxicity. *Exp Ther Med*, 16(5), 4049-4057. <https://doi.org/10.3892/etm.2018.6683>.
- Cakmak R, Basaran E, Boğa M, Erdoğan Ö, et al. 2022. Schiff base derivatives of 4-aminoantipyrine as promising molecules: synthesis, structural characterization, and biological activities. *Russ J Bioorg Chem*, 48(2), 334-344. <https://doi.org/10.1134/S1068162022020182>.
- Chen L, Lv Z, Gao Z, Ge G, et al. 2019. Human β -defensin-3 reduces excessive autophagy in intestinal epithelial cells and in experimental necrotizing enterocolitis. *Scientific Reports*, 9(1), 19890. <https://doi.org/10.1038/s41598-019-56535-3>.
- Danaei GH, Amali A, Karami M, Khorrami, et al., 2022. The significance of thymoquinone administration on liver toxicity of diazinon and cholinesterase activity; a recommendation for prophylaxis among individuals at risk. *BMC Complement Med Ther*, 22(1), 1-8. <https://doi.org/10.1186/s12906-022-03806-8>.
- Eid BG, El-Shitany NA, 2021. Captopril downregulates expression of Bax/cytochrome C/caspase-3 apoptotic pathway, reduces inflammation, and oxidative stress in cisplatin-induced acute hepatic injury. *Biomedicine & Pharmacotherapy*, 139, 111670. <https://doi.org/10.1016/j.biopha.2021.111670>.
- Farooqui Z, Afsar M, Rizwan S, Khan AA, et al., 2016. Oral administration of *Nigella sativa* oil ameliorates the effect of cisplatin on membrane enzymes, carbohydrate metabolism and oxidative damage in rat liver. *Toxicol Rep*, 13(3), 328-335. <https://doi.org/10.1016/j.toxrep.2016.02.004>.
- Fathy M, Darwish MA, Abdelhamid ASM, Alrashedy GM, et al., 2022. Kinetin ameliorates cisplatin-induced hepatotoxicity and lymphotoxicity via attenuating oxidative damage, cell apoptosis and inflammation in rats. *Biomedicines*, 10(7), 1620. <https://doi.org/10.3390/biomedicines10071620>.
- Gianazza E, Brioschi M, Fernandez AM, Banfi C, 2019. Lipoxidation in cardiovascular diseases. *Redox Biol*, 23, 101119. <https://doi.org/10.1016/j.redox.2019.101119>.
- Hagar H, Husain S, Fadda LM, Attia et al., 2019. Inhibition of NF- κ B and the oxidative stress-dependent caspase-3 apoptotic pathway by betaine supplementation attenuates hepatic injury mediated by cisplatin in rats. *Pharmacol Rep*, 71(6), 1025-1033. <https://doi.org/10.1016/j.pharep.2019.06.003>.
- Hassan HM, Al-Wahaibi LH, Elmorsy MA, Mahran YF, 2020. Suppression of cisplatin-induced hepatic injury in rats through alarmin high-mobility group box-1 pathway by *Ganoderma lucidum*: Theoretical and experimental study. *Drug Des Devel Ther*, 2335-2353. <https://doi.org/10.2147/DDDT.S249093>.
- Hatipoglu D, Ozsan M, Dönmez HH, Dönmez N, 2023. Hepatoprotective effects of *nigella sativa* oil against acrylamide-induced liver injury in rats. *Ankara Univ Vet Fak Derg*, 70(4), 419-426. <https://doi.org/10.33988/auvfd.1096306>.
- Hu Y, Sun B, Zhao B, Mei D, et al., 2018. Cisplatin-induced cardiotoxicity with midrange ejection fraction: A case report and review of the literature. *Medicine*, 97(52), e13807. <https://doi.org/10.1097/MD.00000000000013807>.
- Kaya S, Yalcin T, 2023. In an experimental myocardial infarction model, L-arginine pre-intervention may exert cardioprotective effects by regulating OTULIN levels and mitochondrial dynamics. *Cell Stress Chaperones*. <https://doi.org/10.1007/s12192-023-01373-6>.
- Kaya S, Yalcin T, Tektemur A, Kuloğlu T, 2023a. N-Acetylcysteine may exert hepatoprotective effect by regulating Meteorin-Like levels in Adriamycin-induced liver injury. *Cell Stress Chaperones*, 1-11. <https://doi.org/10.1007/s12192-023-01376-3>.
- Kaya S, Yalcin T, Boydak M, Dönmez HH, 2023b. Protective effect of N-acetylcysteine against aluminum-induced kidney tissue damage in rats. *Biol Trace Elem Res*, 201(4), 1806-1815. <https://doi.org/10.1007/s12011-022-03276-6>.
- Neamatallah T, El-Shitany NA, Abbas AT, Ali SS, et al., 2018. Honey protects against cisplatin-induced hepatic and renal toxicity through inhibition of NF- κ B-mediated COX-2 expression and the oxidative stress dependent BAX/Bcl-2/caspase-3 apoptotic pathway. *Food Funct*, 9(7), 3743-3754. <https://doi.org/10.1039/c8fo00653a>.
- Niazvand F, Ashtari A, Chamkouri N, Azari M, 2023. Hepatoprotective effects of *Alpinia officinarum* rhizome extract on cisplatin-induced hepatotoxicity in rats; a biochemical, histopathological and immunohistochemical study. *J Trace Elem Med Biol*, 80, 127306. <https://doi.org/10.1016/j.jtemb.2023.127306>.
- Oz M, Üstüner E, Bölükbaş F, 2023. Effects of dietary black cumin (*Nigella sativa* L.) oil on growth performance, hemato-biochemical and histopathology of cypermethrin-intoxicated Nile tilapia (*Oreochromis niloticus*). *J World Aquac Soc*, 55,273-288. <https://doi.org/10.1111/jwas.13005>.
- Quintanilha JCF, de Sousa VM, Visacri MB, Amaral LS, et al., 2017. Involvement of cytochrome P450 in cisplatin treatment: implications for toxicity. *Cancer Chemother Pharmacol*, 80(2), 223-233. <https://doi.org/10.1007/s00280-017-3358-x>.
- Ramadan SA, Kamel EM, Alruhaimi RS, Bin-Amman A, et al., 2023. An integrated phytochemical, in silico and in vivo approach to identify the protective effect of *Caroxylon salicornicum* against cisplatin hepatotoxicity. *Saudi Pharm J*, 31(10), 101766. <https://doi.org/10.1016/j.jsps.2023.101766>.
- Sadhukhan P, Saha S, Dutta S, Sil PC, 2018. Mangiferin ameliorates cisplatin induced acute kidney injury by upregulating Nrf-2 via the activation of PI3K and exhibits synergistic anticancer activity with cisplatin. *Front Pharmacol*, 9, 638. <https://doi.org/10.3389/fphar.2018.00638>.



- Shahid F, Farooqui Z, Alam T, Abidi S, et al., 2021. Thymoquinone supplementation ameliorates cisplatin-induced hepatic pathophysiology. *Hum Exp Toxicol*, 40(10), 1673-1684. <https://doi.org/10.1177/09603271211003645>.
- Singh N, Magotra R, Sharma AK, Ahmed M, et al., 2015. Effect of cisplatin on liver of male albino rats. *J Evol Med Dent Sci*, 4, 8993-8998. <https://doi.org/10.14260/jemds/2015/1305>.
- Xu H, Qin W, Hu X, Mu S, et al., 2018. Lentivirus-mediated overexpression of OTULIN ameliorates microglia activation and neuroinflammation by depressing the activation of the NF- κ B signaling pathway in cerebral ischemia/reperfusion rats. *J Neuroinflammation*, 15(1), 83. <https://doi.org/10.1186/s12974-018-1117-5>.
- Yalcin T, Kaya S, 2023a. Thymoquinone may alleviate cisplatin-induced muscle atrophy in rats by regulating mitofusin 2 and meteorin-like levels. *Comp Clin Pathol*, 32, 339-345. <https://doi.org/10.1007/s00580-023-03442-9>.
- Yalcin T, Kaya S, 2023b. Resveratrol May Reduce Apoptosis due to Doxorubicin-Induced Hepatotoxicity by Regulating the Bax/Bcl2 Ratio in Male Rats. *Firat Universitesi Saglik Bilimleri Tip Dergisi*, 37(1).
- Yalcin T, Kaya S, Kuloğlu T, 2023. Resveratrol may dose-dependently modulate nephrin and OTULIN levels in a doxorubicin-induced nephrotoxicity model. *Toxicol Mech Methods*, 1-11. <https://doi.org/10.1080/15376516.2023.2268717>.
- Zhang X, Peng X, Wang C, Olatunji OJ, Famurewa A, 2022. Tiliacora triandra attenuates cisplatin triggered hepatorenal and testicular toxicity in rats by modulating oxidative inflammation, apoptosis and endocrine deficit. *Front Biosci*, 27(2), 44. <https://doi.org/10.31083/j.fbl2702044>.

Author Contributions

Motivation/Concept: SK, TY; Design: TY; Control/Supervision: SK; Data Collection and/or Processing: SK, TY; Analysis and/or Interpretation: SK, TY; Literature Review: TY; Writing the Article: SK; Critical Review: SK, TY

Ethical Approval

This study was conducted with the approval of Dicle University Animal Experiments Ethics Committee dated 29/03/2022-259525.

