



## RESEARCH ARTICLE

### Assessment of the protective effects of pomegranate peel extract and N-acetyl cysteine alone or in combination with Ornipural® against Cadmium-induced bone toxicity in rat

Durmus Hatipoglu<sup>1</sup>, İsmail Demircioglu<sup>\*2</sup>, Kursat Filikci<sup>3</sup>, Yasemin Korkmaz<sup>4</sup>, Huseyin Gungor<sup>5</sup>,  
Muhammed Demircioglu<sup>6</sup>, Burak Dik<sup>4</sup>

<sup>1</sup>Department of Physiology, Faculty of Veterinary Medicine, Selcuk University, Konya, Türkiye

<sup>2</sup>Department of Anatomy, Faculty of Veterinary Medicine, Harran University, Şanlıurfa, Türkiye

<sup>3</sup>Department of Pathology, Faculty of Veterinary Medicine, Harran University, Şanlıurfa, Türkiye

<sup>4</sup>Department of Pharmacology and Toxicology, Faculty of Veterinary Medicine, Selcuk University, Konya, Türkiye

<sup>5</sup>Department of Pharmacology and Toxicology, Faculty of Veterinary Medicine, Sivas Cumhuriyet University, Sivas, Türkiye

<sup>6</sup>Department of Histology and Embryology, Institute of Health Sciences, Dicle University, Diyarbakir, Türkiye

Received: 26.12.2023 , Accepted: 28.02.2024

\*idemircioglu@harran.edu.tr

### Siçanlarda kadmiyumun neden olduğu kemik toksisitesine karşı nar kabuğu ekstraktı ve N-asetil sisteinin tek başına veya Ornipural® ile kombinasyonunun koruyucu etkilerinin değerlendirilmesi

Eurasian J Vet Sci, 2024, 40, 1, 24-33

DOI: 10.15312/EurasianJVetSci.2024.422

#### Öz

**Amaç:** Bu çalışma, nar kabuğu ekstresi (PPE) ve N-asetil Sistein (NAC)'in tek başına veya ticari preparat Ornipural® (ORN) ile birlikte kullanımının, deneysel olarak kadmiyum (Cd) indüklenmiş toksisiteye karşı kemik metabolizması üzerindeki etkilerini belirlemek amacıyla yapılmıştır.

**Gereç ve Yöntem:** Çalışmada her grupta 6 adet Wistar Albino siçan olmak üzere toplam 36 hayvan kullanıldı. Hayvanlar kontrol, Cd, Cd+PPE, Cd+NAC, Cd+PPE+ORN ve Cd+NAC+ORN gruplarına atandı. Gruplardaki hayvanlara 8. haftanın sonunda kan örnekleri alındıktan sonra ötenazi uygulandı. Ötenazi sonrasında morfometrik ve histopatolojik incelemeler için kemikler mase-rasyona tabi tutuldu.

**Bulgular:** Tedavi grupları ile Cd grubu arasında histopatolojik değişiklikler (osteoporotik değişiklikler ve kırmızı kemik iliğinde değişiklikler) ve biyo-belirteçler (Ca, P ve Mg) açısından istatistiksel olarak anlamlı farklılıklar belirlendi (P<0.05).

**Öneri:** Deneysel olarak indüklenmiş kadmiyum toksisitesine karşı uygulanan PPE, NAC ve ORN ile birlikte uygulanan tedavi kombinasyonlarının kemik metabolizması üzerinde olumlu etkilerinin olduğu belirlenmiş olmasına rağmen, uygulanan tedavi protokollerinin kesin etkililiğini belirlemek için tedavi süresini ve dozunu artırarak denemeler yapmanın faydalı olacağı düşünülmüştür.

**Anahtar kelimeler:** Kemik toksisitesi, kadmiyum, N-asetil sistein, Ornipural®, nar kabuğu

#### Abstract

**Aim:** The present study was conducted to determine the effects of pomegranate peel extract (PPE) and N-acetyl Cysteine (NAC) alone or in their treatment combinations with commercial preparation Ornipural® (ORN) on bone metabolism against experimentally cadmium (Cd)-induced toxicity in rats.

**Materials and Methods:** Totally 36 animals were used in the study including 6 Wistar Albino rats in each group. The animals were assigned to control, Cd, Cd+PPE, Cd+NAC, Cd+PPE+ORN and Cd+NAC+ORN groups. The animals in the groups were euthanized after their blood samples were taken at the end of the 8<sup>th</sup> week. The bones were subjected to maceration for morphometric and histopathological examinations after euthanasia.

**Results:** The statistically significant differences were determined between the treatment groups and Cd group in terms of histopathological changes (osteoporotic alterations and changes in red bone marrow) and biomarkers (Ca, P and Mg) (P<0.05).

**Conclusion:** Although PPE, NAC and treatment combinations with ORN applied against experimentally induced cadmium toxicity were determined to have positive effects on bone metabolism, it has been thought that carrying out trials by increasing treatment duration and dose would be beneficial to determine definite efficacy of the applied treatment protocols.

**Keywords:** Bone toxicity, cadmium, N-acetyl cysteine, Ornipural®, pomegranate peel

**CITE THIS ARTICLE:** Hatipoglu et al 2024. Assessment of the protective effects of pomegranate peel extract and N-acetyl cysteine alone or in combination with Ornipural® against Cadmium-induced bone toxicity in rat Eurasian J Vet Sci, 40, 1, 24-33





## Introduction

Heavy metals released into environment upon industrialization are increased with every passing day. The exposure to heavy metals such as copper, lead, mercury and cadmium (Cd) at acute and chronic doses seriously threatens public and animal health (Nordberg et al 2018). The production and release of Cd, which is a by-product of zinc, have increased day by day because zinc production has increased, and cadmium has started to be used as a coating material against corrosion (Krone et al 2001). In addition, the increase in industrial wastes and inhalation of cigarette smoke increases Cd exposure (Li et al 2020).

Cd can be taken from contaminated soil primarily through foodstuffs such as vegetables and rice, as well as through other foodstuffs such as shellfish and offal (Satarug et al 2017, Renieri et al 2019). The data obtained from the epidemiological studies including cohort and cross-sectional studies which have indicated that even low environmental exposure to cadmium poses a threat to public health indicated that it is a toxic substance that can damage kidneys, liver, testicles, cardiovascular and endocrine systems (Erdem and Hatipoğlu 2011, Buha et al 2018, Deering et al 2018, Mezynska and Brzoska 2018, Andjelkovic et al 2019, Kisadere et al 2022). It has also been suggested that Cd may contribute to the development of various cancer types in some tissues such as breast, prostate, pancreatic, nasopharynx and bladder (Julin et al 2012, Khlifi et al 2013, Nawrot et al 2015, Wallace et al 2019). Besides, it has been reported that risk for osteoporosis and bone fracture formation increases particularly in the populations occupationally exposed to Cd and humans living in the residential areas contaminated with this contaminant (Kazantzis 2004). It is also considered that osteotoxic effect of Cd is not associated only with high levels of exposure and low environmental Cd levels may also lead to adverse effects (Gallagher et al 2008, Wu et al 2010). Cd accumulated in the body after long-term exposure may be deposited in the bones and cause mineralization impairments, decline in bone mass and increase in bone fracture sensitivity (Jarup and Akesson 2009, James and Meliker 2013). Cd that has a biological half-life of 10-30 years histologically causes hyperplastic enlargement of medulla ossium, accelerates the differentiation of osteoclasts, and increases the activity of mature osteoclasts in bone (Wilson et al 1996). Cd may impair bone metabolism by directly affecting osteoblast and osteoclast functions (Chen et al 2009). Indirectly, it causes a decline in intestinal calcium absorption and thereby impairs bone mineralization by affecting Vitamin D due to its nephrotoxic effect (Bressler et al 2004, Uchida et al 2010). These effects lead to metabolic bone disorders such as osteoporosis and osteomalacia (Berglund et al 2000).

Although substances that inhibit the chelator and toxic

effects reduce Cd toxicity, have insufficient effects. New therapeutic approaches are needed due to the limited heavy metal binding capacity harmful effects of heavy metals in the blood. For this purpose, many natural products (food, air, soil, etc.) and dietary components have been evaluated to reduce the toxic effect of Cd as an environmental pollutant on bone metabolism (Brzoska et al 2015, Li et al 2017, Hatipoglu et al 2024).

Pomegranate peel extract (PPE) is rich in flavonoids and tannins. This part of the fruit has the highest antioxidant capacity and is equivalent to 92% of the total antioxidant activity of this fruit (Al-Rawahi et al 2014). Its composition mainly contains substantial amounts of ellagitannins (ETs) such as punicalagin (PC), punicalin, gallagic acid, ellagic acid (EA), and EA-glycosides (Zhou et al 2015). Tannins are one of the main polyphenol groups in the diet. It has been reported that flavonoids and tannins may be beneficial in preventing of the diseases associated with oxidative stress and inflammation, cardiovascular diseases, cancer and osteoporosis (Lansky and Newman 2007, Ge et al 2021). It has been shown that flavonoids effect osteoporosis (Bellavia et al 2021), inhibits osteoclast differentiation (Al Mamun et al 2020) and stimulates osteoblast formation (An et al 2016). However, their protective effects on bone metabolism in Cd toxicity are unknown. It is stated that PPE can suppress nuclear factor- $\kappa$ B (NF- $\kappa$ B) activation in vascular endothelial cells and reduce oxidative damage by preventing excessive free radical formation (Itoh et al 2014). It can prevent many diseases such as cancer, diabetes, and cardiovascular disease (Aviram et al 2002, Afaq et al 2010, Jain et al 2012). In addition, it is stated that PPE reduces liver and kidney damage caused by Cd and increases antioxidant capacity (El-Daly 2016). PPE is associated with antioxidant activity because it contains significant amounts of phenolic compounds such as anthocyanins, ellagic acid, phytoestrogens, flavonoids, and tannins (Ghasemian et al 2006, Tehranifar et al 2010, Orak et al 2012).

N-acetyl cysteine (NAC) is a cysteine derivative amino acid. It is known that NAC has a chelating effect in removal of metals such as cadmium (Cd), mercury (Hg), chromium (Cr), arsenic (As) and gold (Au) from the body (Evli et al 2020, Hirota and Matsuoka 2021). NAC can exhibit a protective effect against heavy metal toxications by decreasing oxidative stress associated with toxic substance and by chelating (Deng et al 2010). It has been reported that NAC is a more favorable and reliable chelating agent than other chelating agents since it only binds to heavy metals in the tissues (Sisombath and Jalilehvand 2015). At the same time, much toxication-related damage can be reduced with its antioxidant effects. Alak et al. (2019) reported that NAC could reduce oxidative damage caused by cypermethrin by increasing the activity of antioxidant enzymes and decreasing the levels of malondialdehyde (MDA), myeloperoxidase (MPO), 8-OHdG,



and Caspase-3 and that its use as a pro-oxidant has metal chelating properties (Alak et al 2019). In addition, Yedjou et al. (2010) think that NAC may be a promising candidate for chemoprevention against lead toxicity due to its ability to scavenge free radicals (Yedjou et al 2010). Kaplan et al., (2008) reported that exogenously administered NAC can reduce the toxic effects of Cd in the kidney without decreasing tissue Cd level (Kaplan et al 2008).

Ornipural® (ORN) is a veterinary commercial product containing betaine, L-arginine, L-ornithine, L-citrulline and sorbitol. It has hepatoprotective, lyophilic and diuretic properties. Betaine is known as a natural antioxidant (Zhang et al 2016). L-arginine, one of the most functional amino acids in the living cells, is the precursor for cellular signalling molecules such as glutamine and nitric oxide and has a protective effect against Cd toxicity (Liu et al 2006). L-ornithine is the primary substance of the urea cycle that allows the excretion of excess nitrogen by converting ammonia to urea in the liver (Kowalski and Bieniecki 2006). Sorbitol increases the intestinal absorption of many vitamins primarily vitamin B6, vitamin B12 and iron ion. It has also a promotive effect on bile excretion (Lan et al 2021).

Cd toxicity is a critical condition for veterinary medicine and human medicine. Inefficient treatment of this toxicity leads to impairment of bone metabolism. The use of chelating agents or substances that reduce/prevent bone damage in the Cd bone toxicity is necessary for an effective treatment. Therefore, PPE and NAC, which have antioxidant and osteoblastic effects, may be beneficial in Cd-induced bone toxicity. For this purpose, the protective efficacy of PPE and treatment and combinations of ORN, which is used as a supportive agent, were investigated morphometrically, histopathologically and biochemically in the Cd bone toxicity.

## Material and Methods

### Pomegranate Peel Extraction

The extraction of pomegranate peels in the study was carried out according to the method specified by Demir et al. (2019). In this method, after the pomegranate peels were treated with 33% ethanol, 78°C and 113 minutes, the peels were extracted by mixing at a ratio of 200:20 (mL solvent/g plant). The obtained extract was centrifuged at 5000 rpm for 10 minutes. Then, it was filtered through filter paper at room temperature, and the filtrate was concentrated in the evaporator and made ready for use (Demir et al 2019).

### Animal groups and treatment schedule

In the present study, 36 adult male Wistar Albino rats weighing 240±20 g were supplied from the Experimental Medicine Research and Application Centre of Selcuk

University. All rats were kept in a well-ventilated room under standardized housing conditions including constant temperature (25±2°C), humidity of 50% ± 10% and 12-hour light/12-hour dark cycle. All experimental animals were fed a standard laboratory balanced commercial diet and drinking water ad libitum. The animal handling and the study protocol were ethically approved by Animal Experiments Local Ethics Committee of Harran University (Approval No: 2020/003/04). Thirty-six male rats were randomly assigned to six equal groups, each consisting of six rats. The physiological saline solution was administered to the animals in the control group concurrently with the other animals (1 ml/rat/day, oral). The animals in the cadmium group were orally administered Cd at a dose of 5 mg/kg/day (Jacobó-Estrada et al 2017). The animals in the Cd+PPE group were orally administered Cd at a dose of 5 mg/kg/day 30 minutes after oral administration of pomegranate peel extract (PPE) at a dose of 500 mg/kg/day (Jafri et al., 2000). The animals in the Cd+NAC group were orally administered Cd at a dose of 5 mg/kg/day 30 minutes after oral administration of N-acetyl Cysteine (NAC) at a dose of 100 mg/kg/day (Abdel-Wahab and Moussa, 2019). The animals in the Cd+PPE+ORN group were orally administered Cd at a dose of 5 mg/kg/day 30 minutes after oral administration of pomegranate peel extract (PPE) at a dose of 500 mg/kg/day in combination with subcutaneous administration of Ornipural® at a dose of 1 ml/kg. The animals in the Cd+NAC+ORN group were orally administered Cd at a dose of 5 mg/kg/day 30 minutes after oral administration of N-acetyl Cysteine (NAC) at a dose of 100 mg/kg/day in combination with subcutaneous

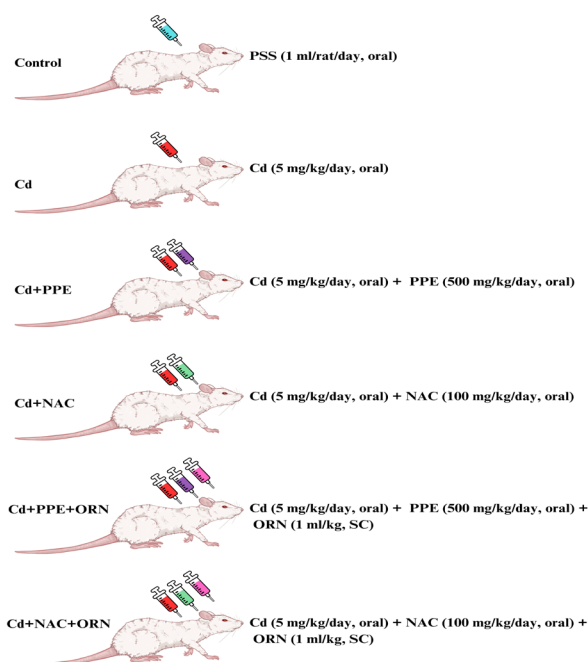


Figure 1. Experimental design illustrating the distribution of groups. CD: Cadmium, NAC: N-acetyl Cysteine, ORN: Ornipural, PPE: Pomegranate peel extract, PSS: Physiological saline solution, SC: Subcutaneous. The applications of PPE, NAC, and Orn were performed half an hour after Cd administration





administration of Ornipural® at a dose of 1 ml/kg (Figure 1).

### *The evaluation of serum Ca, P, and Mg levels*

The serum samples were kept at -20°C until they were analyzed. Calcium (Ca), magnesium (Mg) and inorganic phosphorus (P) were measured from the serum samples using commercial reagents and Beckman Coulter analyzer (AU 480, Beckman Coulter, Brea, CA, USA) according to the standards.

### *Morphometric examination*

Bone maceration was carried out in the animals after performing euthanasia procedure. After completion of maceration procedures, bones were scanned at 0.625 mm section thickness, 80 kv, 200 MA and 639 mGY in the 64-slice Multidetector Computed Tomography (MDCT) device. Prokop (2003) and Kalra (2004) were taken as references for scanning and dose protocols (Kalra et al., 2004). Three-dimensional (3D) modeling was created using MIMICS 20.1 (The Materialise Group, Leuven, Belgium) software from the images recorded in the format of DICOM (Digital Imaging and Communications in Medicine). The bones' volume and surface area data were obtained from the 3D models. The volume and surface area data were analyzed involving all the bones of the extremities except for scapula and ossa coxae.

### *Histopathological examination*

After the bones of the rats were fixed in 10% neutral formaldehyde (Merck, Germany), they were kept in 10% EDTA solution (Merck, Germany) until appropriate hardness was obtained. The samples were trimmed and placed in the cassettes (Isolab, Germany). Afterward, the samples were washed for 12 hours in the running tap water. Later, the tissues were taken to routine tissue processor (Leica TP1020, Germany) and blocked in paraffin (Thermo Electron Corp. Shandon Histocentre 3). The 5- $\mu$ m thick sections prepared from each block using microtome (Leica RM2255, Germany) were stained based on Harris's Haematoxylin-Eosin (HE) method in the automated stainer (Leica Autostainer XL, Germany) after the deparaffinisation and rehydration stages. The stained preparations were covered with coverslip (Citotest, China) in the automated glass coverslipper device (Leica CV5030). All results were evaluated under light microscope (Olympus BX51, Japan) and appropriate fields were photographed (Olympus DP71, Japan).

### *Statistics analysis*

IBM SPSS Statistics 25.0 (SPSS, Inc., Chicago, IL, USA) software package was used to analyse the data statistically to determine the significance of inter-group differences. Data regarding bone surface area and calcium, phosphorus and magnesium

levels obtained as a result of the research showed a normal distribution, but histopathological scoring analysis data did not show a normal distribution. For this reason, normally distributed data were carried out with one-way analysis of variance (ANOVA) test. The intragroup comparisons were conducted using an appropriate advanced analysis (Post Hoc, Duncan). The histopathological data were analyzed using Kruskal-Wallis's method (a non-parametric test) and post hoc Dunn-Bonferroni test. The  $P < 0.05$  value was accepted as statistically significant for differences between mean values of the groups. All the variables were expressed as mean  $\pm$  standard error mean (SEM).

## **Results**

### *Serum mineral levels in cadmium-induced toxicity and NAC, PPE and ORN treatment effects*

The analysis of the data obtained from the serum samples in the trial demonstrated that Ca, P and Mg levels of the Cd group were statistically significantly lower than the other treatment groups (C, Cd+NAC, Cd+PPE, Cd+NAC+ORN, Cd+PPE+ORN) ( $P < 0.05$ ). Administration of Pomegranate Peel Extract (Cd+PPE) and N-Acetyl Cysteine (Cd+NAC) significantly improved Ca and Mg levels in these treatment groups compared to Cd group ( $P < 0.05$ ). Furthermore, ORN treatment combined with these substances (Cd+NAC+ORN and Cd+PPE+ORN) showed a similar effect ( $P < 0.05$ ). A significant increase of P level was noticed in the Cd+NAC and Cd+NAC+ORN groups than the Cd group ( $P < 0.05$ ); whereas this increase in the Cd+PPE and Cd+PPE+ORN groups was not significant compared to Cd group ( $P > 0.05$ ) (Figure 2).

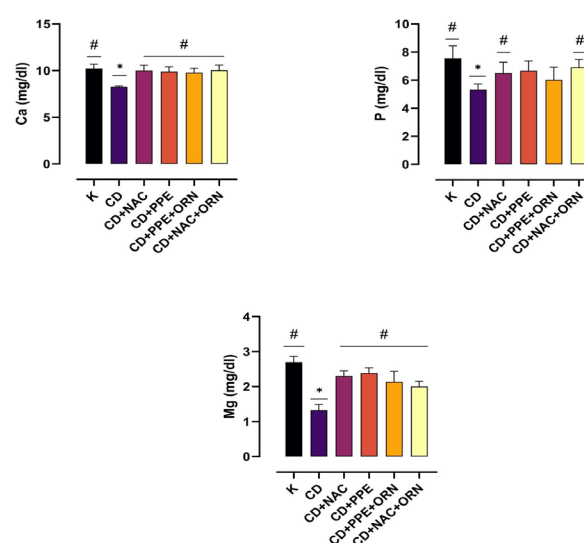


Figure 2. Serum calcium (Ca), phosphorus (P), and magnesium (Mg) levels. (Statistically significant differences are indicated by \* when compared with the control group ( $P < 0.05$ ), statistically significant differences are indicated by # when compared with the CD group ( $P < 0.05$ ). K; control.



	Control	Cd+Nac	Cd+PPE	Cd+PPE+ORN	Cd+NAC+ORN	Cd	SEM	P
Front leg volume (mm <sup>3</sup> )	895,31 <sup>b</sup>	899,66 <sup>b</sup>	910,6 <sup>b</sup>	820,94 <sup>b</sup>	1172,53 <sup>a</sup>	894,26 <sup>b</sup>	21,31	***
Front leg surface (mm <sup>2</sup> )	1290,08 <sup>b</sup>	1207,55 <sup>bc</sup>	1122,96 <sup>c</sup>	1225,68 <sup>bc</sup>	1456,99 <sup>a</sup>	1228,16 <sup>bc</sup>	23,52	**
Hind leg volume (mm <sup>3</sup> )	2376,12 <sup>a</sup>	2244,68 <sup>ab</sup>	2372,60 <sup>a</sup>	2066,35 <sup>b</sup>	2281,26 <sup>ab</sup>	2118,45 <sup>b</sup>	32,90	*
Hind leg surface (mm <sup>2</sup> )	2725,79	2630,65	2498,50	2560,66	2605,21	2513,16	28,32	NS

a,b,c: Values within a row with different superscripts differ significantly at P<0.05 \*P<0.05, \*\*p<0.01, \*\*\*p<0.001, NS:p>0.05, SEM: Standard Error of Mean

### *Cadmium-induced rat forelimbs and hindlimbs changes: Effects of NAC, PPE and ORN*

Table 1 shows mean volume and surface areas of forelimbs and hindlimbs of the rats, SEM values, and intergroup statistical analysis data of the animals. Forelimb volume values were statistically significant in Cd+NAC+ORN group compared to the other groups (P<0.001). No statistically significant difference was identified between the other groups (P>0.05). Forelimb surface area values were statistically significantly different in Cd+NAC+ORN and Cd+PPE groups compared to the other groups (P<0.01). Hindlimb volume values of the control and Cd+PPE groups were similar and higher than the other groups (P<0.05). Cd+PPE+ORN and Cd groups were statistically similar and lower than the other groups (P<0.05).

### *Effects of NAC, ORN, and PPE on Osteoporotic Changes in Cadmium-Induced Rat Models*

The most remarkable result of the histopathological examination was osteoporotic alterations. This situation appeared as particularly sporadic tapering and microfractures in the trabeculae and the expansion of channels and lacunae (Figure 3). The control group showed normal histological appearance of the bone and articular surfaces in the microscopic examination. No pathological finding was observed. Cd group was the group that the most severe osteoporotic alterations were observed in the histopathological examination. Numerous vacuoles were observed in the red bone marrow and mild hyperaemias were present. The osteoporotic alterations in the Cd+PPE group were less severe than the Cd group. The expansion of lacunae and channels was particularly prominent in this group. The less severe osteoporotic alterations were observed also in the Cd+NAC group compared to the Cd group. The increased number of vacuoles in the red bone marrow was observed also in this group; however, no significant difference was determined in terms of severity compared to the Cd group. More mildly osteoporotic alterations were observed in the Cd+PPE+ORN group compared to the Cd group. The vacuolization in the red bone marrow was

milder. The osteoporotic alterations were remarkable in the Cd+NAC+ORN group. However, these alterations were milder than Cd group and more severe than Cd+NAC group. The increased number of vacuoles in the red bone marrow was observed also in this group; however, it was less severe than the Cd group and mild hyperaemia were present. Table 2 shows the statistical analysis of osteoporotic alterations and vacuolization values in the red bone marrow. A significant difference was determined between the control group and other groups (Cd and treatment groups) in the analysis of osteoporotic alterations and vacuolization in the red bone marrow (P<0.05). However, no difference was identified between the treatment groups (P>0.05).

Table 2 shows the statistical analysis of osteoporotic alterations and vacuolization values in the red bone marrow. A significant difference was determined between the control group and other groups (Cd and treatment groups) in the analysis of osteoporotic alterations and vacuolization in the red bone marrow (P<0.05). However, no difference was identified between the treatment groups (P>0.05).

## **Discussion**

As the amounts of heavy metal releasing into environment increases, intake levels of these heavy metals by the living organisms also increase. Cd exposure causes primarily many metabolic disorders that affect bone metabolism such as osteoporosis and osteomalacia. Cd exposure led to impairments in bone mineralization and impaired bone biomechanics (Staessen et al 1999, Buha et al 2019). In the present study, the effects of PPE, NAC, and combinations with ORN on bone metabolism after the experimentally induced Cd bone toxicity were examined and their treatment efficacies were compared.

It has been stated that bone resorption cycles which repair microfractures in the bone and regulate bone structure in response to stress are impaired by exposure to toxic substances such as Cd and the impaired bone resorption leads to osteoporosis (Manolagas 2000, Dempster 2002). Osteoporosis is a chronic disease characterized by declined

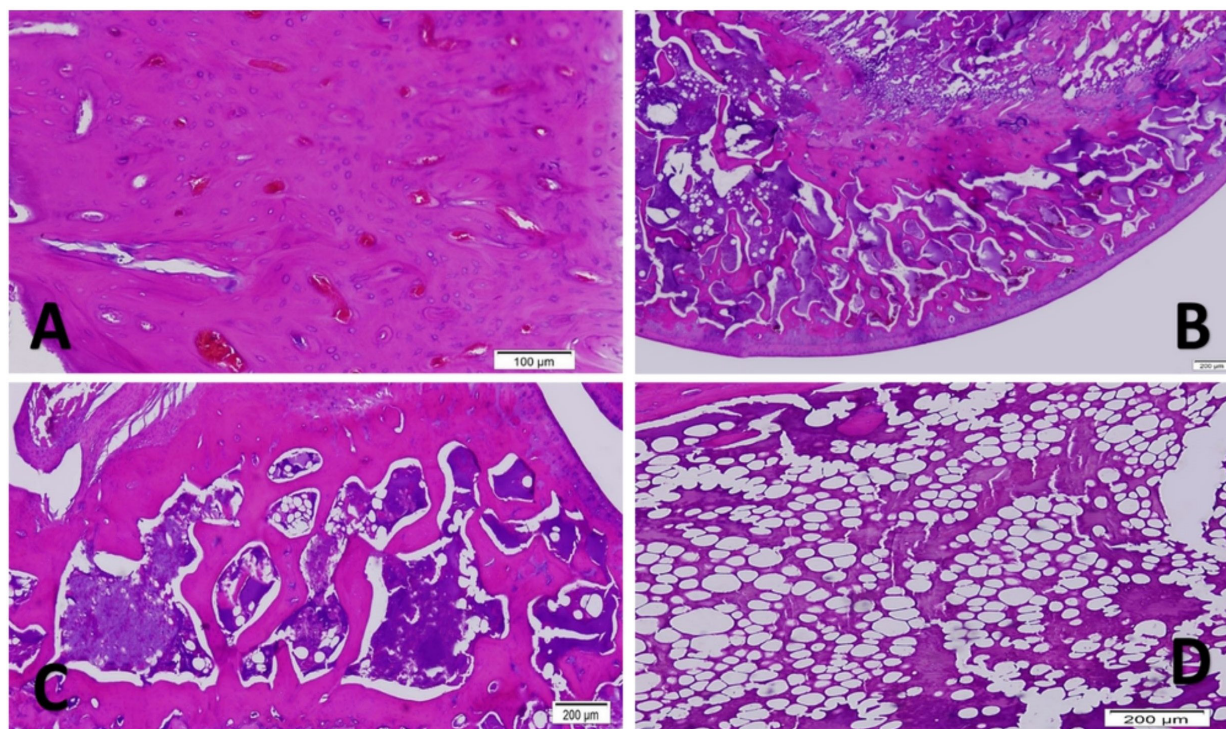


Figure 3. Histopathological changes. A; Hyperemia, CD + NAC + ORN group, Humerus, HE staining. B; Osteoporotic changes in bone trabeculae; Femur, CD group, HE staining. C; Control group, Femur, HE staining. D; Increase in the number of fat vacuoles in the bone marrow, scapula, CD + NAC group, HE staining

Table 2. Histopathological scorings		
	Osteoporotic Changes	Vacuolization in Red Bone Marrow
Control	0	0
CD	3 *	2 *
CD+PPE	2 *	1 *
CD+NAC	2,5 *	2 *
CD+PPE+ORN	3 *	1 *
CD+NAC+ORN	2,5 *	1,5 *

\* : For each parameter, it indicates a significant difference versus the healthy control group ( $p < 0.05$ ). CD: Cadmium, NAC: N-acetyl Cysteine, ORN: Ornipural, PPE: Pomegranate peel extract,

bone mineral density, impaired bone strength and increased risk for bone fracture (Yogesh 2020). It was remarkable in the analysis of histopathological data obtained from the present study that osteoporotic alterations observed in the bones were more severe in the Cd group than in the other groups and mild hyperemia was present as well as numerous vacuoles in the red bone marrow. The statistically lower levels of bone metabolism biomarkers (Ca, P and Mg) due to Cd toxication compared to the control group sported the histopathological findings. Observation of this significant decline particularly in the levels of Ca and P together with osteoporotic alterations suggests that Cd toxication causes impairment of bone metabolism and loss of Ca in urine by leading to nephropathy (Jin et al 2004). Additionally, the studies have revealed that Cd may lead to pathological changes in bone formation and resorption by decreasing intestinal absorption of calcium, affecting bone

cells and calcium and interfering with collagen production in the bone cells (Bernard and Lauwerys 1986, Alfven et al 2000). As a result, the current study supported by morphological, histopathological and biochemical analyses suggests that Cd may cause osteoporosis by affecting bone metabolism, especially Ca, P and Mg. Similar results of changes in Ca, P, and Mg levels have been observed in other studies (Chakraborty et al 2013, Andjelkovic et al 2019). Nevertheless, the studies results on the relationship between Cd exposure and osteoporosis are inconsistent. Songprasert et al (2015) and Li et al (2020) have reported that excessive exposure and intake of Cd causes declined bone density and osteoporosis. In addition, Nawrot et al (2010) have stated that occupational exposure to Cd leads to increased calcium excretion, declined bone density and increased clinical osteoporosis in the middle-aged males even in the absence of renal dysfunction. However, Trzcinka-



Ochocka et al (2010) suggested that Cd was not associated with osteoporosis and bone density. These differences in the literature suggested that it might have been associated with the fact that pathophysiology of this toxic substance has not been precisely clarified and the applied species, doses and exposure duration were different.

PPE contains anthocyanin, a chemical compound that plays an important role in the increased bone cell proliferation, remodelling of the bone and osteoblast differentiation (Trimurni and Putra 2020). In addition, PPE that contains flavonoids in its structure shows a weak oestrogen-like effect in various tissues by binding to ER- $\alpha$  and ER- $\beta$ . Flavonoids can control the activity of CYP19, which is an important enzyme in interaction with oestrogen receptors and oestrogen biosynthesis, and/or steroid dehydrogenases (for instance, 11 $\beta$ -hydroxysteroid dehydrogenase) (Shirwaikar et al 2003). These effects protect against bone loss and decrease osteoporotic impacts. It was noticed in the present study that osteoporotic alterations caused by Cd toxication progressed less severely with PPE supplementation and serum Ca and Mg levels showed a tendency to improve. Similar results were encountered also in the Cd+PPE+ORN group. Besides, it was determined that PPE and control groups were morphometrically similar regarding hindlimb volume values. This result supports the anti-osteoporotic effect of this rich-content flavonoid that contains the ellagitannins (ETs) particularly such as punicalagin (PC), punicalin, gallagic acid, ellagic acid (EA) and EA-glycosides in its composition. Spilmont et al (2015) reported that PPE metabolites can directly modulate bone cell differentiation by enhancing resorption with anti-inflammatory and antioxidant effects in the bone microenvironment. Also, Satpathy et al (2013) stated that EA caused an increase in femoral bone mineral density in ovariectomized rats due to its estrogenic solid activity. These data suggest that using PPE as a complementary therapeutic agent can prevent the reduction in bone mineral density and deterioration of bone microarchitecture due to Cd toxicity.

NAC is a cysteine-derivative amino acid. It has been reported that NAC has chelating effects in removal of metals such as Cd, Hg, and As from the body (Blanusa et al 2005). It has been also stated that NAC with antioxidant characteristics functions as free radical scavengers and increases glutathione levels (Giustarini et al 2018, Zhitkovich 2019). NAC can exhibit a protective effect against heavy metal toxications by decreasing oxidative stress associated with toxic substances and due to its chelating property (Poli et al 2021). It has been reported that NAC is a more favourable and reliable chelating agent than other chelating agents since it only binds to heavy metals in the tissues (Sisombath and Jalilehvand 2015). It has been reported that exogenously administered NAC can reduce the toxic effects of Cd in the kidney without decreasing tissue Cd level (Kaplan et al 2008). In the present study, although treatments of NAC and NAC+ORN administered to regulate the bone metabolism against Cd toxication improved Ca, P, and Mg levels morphometric and histopathological

data of the changes observed in bone metabolism in Cd toxication indicated that these treatment options decreased the osteoporotic alterations, however, this effect was not significant. It was reported in a study investigated the effect of low-dose cadmium on femur morphometry and bone mineral density that no significant correlation was present (Cömelekoglu et al 2007). Ogoshi et al (1992) stated in their study that calcium and phosphorus values were not significantly correlated with bone morphometry. Also in the present study, no significant correlation was found between the physiological parameters and morphometric data and it was thought that this result stemmed from the inadequate treatment durations or doses.

## Conclusion

Cd can cause toxic effects on bone metabolism. Advanced studies may be needed to more accurately determine the impact of Cd exposure on bone metabolism. Additionally, Cd may play a significant role in bone health, and this toxic element could be a crucial determinant factor in osteoporosis. Despite similar positive effects observed in treatment combinations containing PPE, NAC, and ORN, conducting further advanced trials with increased treatment duration and dosage could be useful in determining the exact efficacy of the treatments.

## Conflict of Interest

Author(s) declare(s) that there are no conflicts of interest related to the publication of this article.

## Funding

This research received no external funding.

## References

- Abdel-Wahab, Wessam M, Farouzia I. Moussa. 2019. Neuroprotective effect of N-acetylcysteine against cisplatin-induced toxicity in rat brain by modulation of oxidative stress and inflammation. *Drug Des Devel Ther*, 13, 1155-62. <https://doi.org/10.2147/DDDT.S191240>.
- Afaq F, Khan N, Syed DN, Mukhtar H, 2010. Oral feeding of pomegranate fruit extract inhibits early biomarkers of UVB radiation-induced carcinogenesis in SKH-1 hairless mouse epidermis. *Photochem Photobiol*, 86(6), 1318-1326. <https://doi.org/10.1111/j.1751-1097.2010.00815.x>.
- Al-Rawahi AS, Edwards G, Al-Sibani M, Al-Thani G, et al., 2014. Phenolic constituents of pomegranate peels (*Punica granatum* L.) cultivated in Oman. *European J Med Plants*, 4(3), 315-331. <https://doi.org/10.9734/EJMP/2014/6417>.
- Al Mamun MA, Asim MMH, Sahin MAZ, Al-Bari MAA, 2020. Flavonoids compounds from *Tridax procumbens* inhibit osteoclast differentiation by down-regulating c-Fos activation. *J Cell Mol Med*, 24(4), 2542-2551. <https://doi.org/10.1111/jcmm.14948>.
- Alak G, Yeltekin AC, Ozgeris FB, Parlak V, et al., 2019.







- Therapeutic effect of N- acetyl cysteine as an antioxidant on rainbow trout's brain in cypermethrin toxicity. *Chemosphere*, 221, 30-36. <https://doi.org/10.1016/j.chemosphere.2018.12.196>.
- Alfven T, Elinder C, Carlsson M, Grubb A, et al., 2000. Low-level cadmium exposure and osteoporosis *J Bone Miner Res* 15 (8): 1579-1586. <https://doi.org/10.1359/jbmr.2000.15.8.1579>.
- An J, Yang H, Zhang Q, Liu C, et al., 2016. Natural products for treatment of osteoporosis: The effects and mechanisms on promoting osteoblast-mediated bone formation. *Life Sci*, 147, 46-58. <https://doi.org/10.1016/j.lfs.2016.01.024>.
- Andjelkovic M, Buha Djordjevic A, Antonijevic E, Antonijevic B, et al., 2019. Toxic Effect of Acute Cadmium and Lead Exposure in Rat Blood, Liver, and Kidney. *Int J Environ Res Public Health*, 16(2), 274. <https://doi.org/10.3390/ijerph16020274>.
- Aviram M, Dornfeld L, Kaplan M, Coleman R, et al., 2002. Pomegranate juice flavonoids inhibit low-density lipoprotein oxidation and cardiovascular diseases: studies in atherosclerotic mice and in humans. *Drugs Exp Clin Res*, 28(2-3), 49-62.
- Bellavia D, Dimarco E, Costa V, Carina V, et al., 2021. Flavonoids in Bone Erosive Diseases: Perspectives in Osteoporosis Treatment. *Trends Endocrinol Metab*, 32(2), 76-94. <https://doi.org/10.1016/j.tem.2020.11.007>.
- Berglund M, Akesson A, Bjellerup P, Vahter M, 2000. Metal-bone interactions. *Toxicol Lett*, 112-113, 219-225. [https://doi.org/10.1016/s0378-4274\(99\)00272-6](https://doi.org/10.1016/s0378-4274(99)00272-6).
- Bernard A, Lauwerys R, 1986. Effects of Cadmium Exposure in Humans. In: Cadmium. Eds: Foulkes EC. Berlin, Heidelberg: Springer Berlin Heidelberg, p. 135-177.
- Blanusa M, Varnai VM, Piasek M, Kostial K, 2005. Chelators as antidotes of metal toxicity: therapeutic and experimental aspects. *Curr Med Chem*, 12(23), 2771-2794. <https://doi.org/10.2174/092986705774462987>.
- Bressler JP, Olivi L, Cheong JH, Kim Y, et al., 2004. Divalent metal transporter 1 in lead and cadmium transport. *Ann N Y Acad Sci*, 1012(1), 142-152. <https://doi.org/10.1196/annals.1306.011>.
- Brzoska MM, Rogalska J, Galazyn-Sidorczuk M, Jurczuk M, et al., 2015. Protective effect of Aronia melanocarpa polyphenols against cadmium-induced disorders in bone metabolism: a study in a rat model of lifetime human exposure to this heavy metal. *Chem Biol Interact*, 229, 132-146. <https://doi.org/10.1016/j.cbi.2015.01.031>.
- Buha A, Jugdaohsingh R, Matovic V, Bulat Z, et al., 2019. Bone mineral health is sensitively related to environmental cadmium exposure- experimental and human data. *Environ Res*, 176, 108539. <https://doi.org/10.1016/j.envres.2019.108539>.
- Buha A, Matovic V, Antonijevic B, Bulat Z, et al., 2018. Overview of Cadmium Thyroid Disrupting Effects and Mechanisms. *Int J Mol Sci*, 19(5), 1501. <https://doi.org/10.3390/ijms19051501>.
- Chakraborty S, Dutta AR, Sural S, Gupta D, et al., 2013. Ailing bones and failing kidneys: a case of chronic cadmium toxicity. *Ann Clin Biochem*, 50(5), 492-495. <https://doi.org/10.1177/0004563213481207>.
- Chen X, Zhu G, Gu S, Jin T, et al., 2009. Effects of cadmium on osteoblasts and osteoclasts in vitro. *Environ Toxicol Pharmacol*, 28(2), 232-236. <https://doi.org/10.1016/j.etap.2009.04.010>.
- Cömelekoglu Ü, Yalin S, Bagis S, Yildiz A, et al., 2007. Kadmiyumun Kortikal Kemik Mineral Yoğunluğu ve Biyomekanik Parametreleri Üzerine Etkisi: Ovariektomili Sıçan Modeli ile Karşılaştırma. *Türk J Phys Med Rehab*, 53(1). 1-4.
- Deering KE, Callan AC, Prince RL, Lim WH, et al., 2018. Low-level cadmium exposure and cardiovascular outcomes in elderly Australian women: A cohort study. *Int J Hyg Environ Health*, 221(2), 347-354. <https://doi.org/10.1016/j.ijheh.2017.12.007>.
- Demir T, Akpınar Ö, Haki K, Güngör H, 2019. Nar (*Punica granatum* L.) kabuğunun in vitro antidiyabetik, antienflamatuar, sitotoksik, antioksidan ve antimikrobiyal aktivitesi. *Akademik Gıda*, 17(1), 61-71. <https://doi.org/10.24323/akademik-gida.544647>.
- Dempster DW, 2002. The impact of bone turnover and bone-active agents on bone quality: focus on the hip. *Osteoporos Int*, 13(5), 349-352. <https://doi.org/10.1007/s001980200038>.
- Deng X, Xia Y, Hu W, Zhang H, et al., 2010. Cadmium-induced oxidative damage and protective effects of N-acetyl-L-cysteine against cadmium toxicity in *Solanum nigrum* L. *J Hazard Mater*, 180(1-3), 722-729. <https://doi.org/10.1016/j.jhazmat.2010.04.099>.
- El-Daly AA, 2016. Pomegranate peel Extract Protects Cadmium-induced nephrotoxicity in albino mice. *J Biosci Appl Res*, 2(6), 362-375. <https://doi.org/10.21608/jbaar.2016.108529>.
- Erdem T, Hatipoğlu F, 2011. Pathology of single dose cadmium toxicity and investigations of protective effect of simultaneous chlorpromazine administrations in rats. *Eurasian J Vet Sci*, 27(1), 45-58.
- Evli S, Karagözler AA, Güven G, Orhan H, et al., 2020. Heavy metal removal by N-acetylcysteine-functionalized cryogels. *Bullet Mater Sci*, 43(1), 107. <https://doi.org/10.1007/s12034-020-2060-5>.
- Gallagher CM, Kovach JS, Meliker JR, 2008. Urinary cadmium and osteoporosis in U.S. Women >or= 50 years of age: NHANES 1988-1994 and 1999-2004. *Environ Health Perspect*, 116(10), 1338-1343. <https://doi.org/10.1289/ehp.11452>.
- Ge S, Duo L, Wang J, GegenZhula, et al., 2021. A unique understanding of traditional medicine of pomegranate, *Punica granatum* L. and its current research status. *J Ethnopharmacol*, 271, 113877. <https://doi.org/10.1016/j.jep.2021.113877>.
- Ghasemian A, Mehrabian S, Majd A, 2006. Peel extracts of two Iranian cultivars of pomegranate (*Punica granatum*) have antioxidant and antimutagenic activities. *Pak J Biol Sci*, 9(7), 1402-1405. <https://doi.org/10.3923/pjbs.2006.1402.1405>.
- Giustarini D, Galvagni F, Dalle Donne I, Milzani A, et al., 2018. N-acetylcysteine ethyl ester as GSH enhancer in human primary endothelial cells: A comparative study with other drugs. *Free Radic Biol Med*, 126, 202-209. <https://doi.org/10.1016/j.freeradbiomed.2018.08.013>.
- Hatipoglu D, Ates MB, Senturk G, Bulut A, 2024. Metabolomic modelling and neuroprotective effects of carvacrol against





- acrylamide toxicity in rat's brain and sciatic nerve. *Clin Exp Pharmacol Physiol*, 51(3), e13841. <https://doi.org/10.1111/1440-1681.13841>.
- Hirota K, Matsuoka M, 2021. N-acetylcysteine restores the cadmium toxicity of *Caenorhabditis elegans*. *Biometals*, 34(5), 1207-1216. <https://doi.org/10.1007/s10534-021-00322-z>.
- Itoh H, Iwasaki M, Sawada N, Takachi R, et al., 2014. Dietary cadmium intake and breast cancer risk in Japanese women: a case-control study. *Int J Hyg Environ Health*, 217(1), 70-77. <https://doi.org/10.1016/j.ijheh.2013.03.010>.
- Jacobo-Estrada T, Santoyo-Sánchez M, Thévenod F, Barbier O, 2017. Cadmium Handling, Toxicity and Molecular Targets Involved during Pregnancy: Lessons from Experimental Models. *Int J Mol Sci*, 18(7), 1590. <https://doi.org/10.3390/ijms18071590>.
- Jafri MA, M Aslam, K Javed, S Singh. 2000. Effect of *Punica granatum* Linn. (flowers) on blood glucose level in normal and alloxan-induced diabetic rats. *J Ethnopharmacol*, 70(3), 309-314. [https://doi.org/10.1016/S0378-8741\(99\)00170-1](https://doi.org/10.1016/S0378-8741(99)00170-1).
- Jain V, Viswanatha GL, Manohar D, Shivaprasad HN, 2012. Isolation of Antidiabetic Principle from Fruit Rinds of *Punica granatum*. *Evid Based Complement Alternat Med*, 2012, 147202. <https://doi.org/10.1155/2012/147202>.
- James KA, Meliker JR, 2013. Environmental cadmium exposure and osteoporosis: a review. *Int J Public Health*, 58(5), 737-745. <https://doi.org/10.1007/s00038-013-0488-8>.
- Jarup L, Akesson A, 2009. Current status of cadmium as an environmental health problem. *Toxicol Appl Pharmacol*, 238(3), 201-208. <https://doi.org/10.1016/j.taap.2009.04.020>.
- Jin T, Nordberg G, Ye T, Bo M, et al., 2004. Osteoporosis and renal dysfunction in a general population exposed to cadmium in China. *Environ Res*, 96(3), 353-359. <https://doi.org/10.1016/j.envres.2004.02.012>.
- Julin B, Wolk A, Johansson JE, Andersson SO, et al., 2012. Dietary cadmium exposure and prostate cancer incidence: a population-based prospective cohort study. *Br J Cancer*, 107(5), 895-900. <https://doi.org/10.1038/bjc.2012.311>.
- Kaplan M, Atakan IH, Aydogdu N, Aktöz T, et al., 2008. Influence of N-acetylcysteine on renal toxicity of cadmium in rats. *Pediatr Nephrol*, 23(2), 233-241. <https://doi.org/10.1007/s00467-007-0696-7>.
- Kazantzis G, 2004. Cadmium, osteoporosis and calcium metabolism. *Biometals*, 17(5), 493-498. <https://doi.org/10.1023/b:biom.0000045727.76054.f3>.
- Khlifi R, Olmedo P, Gil F, Hammami B, et al., 2013. Arsenic, cadmium, chromium and nickel in cancerous and healthy tissues from patients with head and neck cancer. *Sci Total Environ*, 452-453, 58-67. <https://doi.org/10.1016/j.scitotenv.2013.02.050>.
- Kisadere I, Karaman M, Aydin MF, Donmez N, et al., 2022. The protective effects of chitosan oligosaccharide (COS) on cadmium-induced neurotoxicity in Wistar rats. *Arch Environ Occup Health*, 77(9), 755-763. <https://doi.org/10.1080/19338244.2021.2008852>.
- Kowalski P, Bieniecki M, 2006. Pharmacokinetics and bioavailability study of L-ornithine-L-aspartate in healthy volunteers--a comparative study of two oral formulations. *J Pharm Biomed Anal*, 41(3), 1061-1064. <https://doi.org/10.1016/j.jpba.2006.01.049>.
- Krone CA, Wyse EJ, Ely JT, 2001. Cadmium in zinc-containing mineral supplements. *Int J Food Sci Nutr*, 52(4), 379-382. <https://doi.org/10.1080/09637480120057602>.
- Lan RT, Ren Y, Wei X, Tang LZ, et al., 2021. Synergy between vitamin E and D-sorbitol in enhancing oxidation stability of highly crosslinked ultrahigh molecular weight polyethylene. *Acta Biomater*, 134, 302-312. <https://doi.org/10.1016/j.actbio.2021.07.041>.
- Lansky EP, Newman RA, 2007. *Punica granatum* (pomegranate) and its potential for prevention and treatment of inflammation and cancer. *J Ethnopharmacol*, 109(2), 177-206. <https://doi.org/10.1016/j.jep.2006.09.006>.
- Li H, Wallin M, Barregard L, Sallsten G, et al., 2020. Smoking-Induced Risk of Osteoporosis Is Partly Mediated by Cadmium From Tobacco Smoke: The MrOS Sweden Study. *J Bone Miner Res*, 35(8), 1424-1429. <https://doi.org/10.1002/jbmr.4014>.
- Li X, Jiang X, Sun J, Zhu C, et al., 2017. Cytoprotective effects of dietary flavonoids against cadmium-induced toxicity. *Ann NY Acad Sci*, 1398(1), 5-19. <https://doi.org/10.1111/nyas.13344>.
- Li X, Li R, Yan J, Song Y, et al., 2020. Co-exposure of cadmium and lead on bone health in a southwestern Chinese population aged 40-75 years. *J Appl Toxicol*, 40(3), 352-362. <https://doi.org/10.1002/jat.3908>.
- Liu JH, Nada K, Honda C, Kitashiba H, et al., 2006. Polyamine biosynthesis of apple callus under salt stress: importance of the arginine decarboxylase pathway in stress response. *J Exp Bot*, 57(11), 2589-2599. <https://doi.org/10.1093/jxb/erl018>.
- Manolagas SC, 2000. Birth and Death of Bone Cells: Basic Regulatory Mechanisms and Implications for the Pathogenesis and Treatment of Osteoporosis. *Endocr Rev*, 21(2), 115-137. <https://doi.org/10.1210/edrv.21.2.0395>.
- Mezynska M, Brzoska MM, 2018. Environmental exposure to cadmium-a risk for health of the general population in industrialized countries and preventive strategies. *Environ Sci Pollut Res Int*, 25(4), 3211-3232. <https://doi.org/10.1007/s11356-017-0827-z>.
- Nawrot T, Geusens P, Nulens TS, Nemery B, 2010. Occupational cadmium exposure and calcium excretion, bone density, and osteoporosis in men. *J Bone Miner Res*, 25(6), 1441-1445. <https://doi.org/10.1002/jbmr.22>.
- Nawrot TS, Martens DS, Hara A, Plusquin M, et al., 2015. Association of total cancer and lung cancer with environmental exposure to cadmium: the meta-analytical evidence. *Cancer Causes Control*, 26(9), 1281-1288. <https://doi.org/10.1007/s10552-015-0621-5>.
- Nordberg GF, Bernard A, Diamond GL, Duffus JH, et al., 2018. Risk assessment of effects of cadmium on human health (IUPAC Technical Report). *Pure Appl Chem*, 90(4), 755-808. <https://doi.org/10.1515/pac-2016-0910>.
- Ogoshi K, Nanzai Y, Moriyama T, 1992. Decrease in bone strength of cadmium-treated young and old rats. *Arch Toxicol*, 66(5), 315-320. <https://doi.org/10.1007/BF01973625>.
- Orak HH, Yagar H, Isbilir SS, 2012. Comparison of antioxidant





- activities of juice, peel, and seed of pomegranate (*Punica granatum L.*) and inter-relationships with total phenolic, Tannin, anthocyanin, and flavonoid contents. *Food Sci Biotechnol*, 21(2), 373-387. <https://doi.org/10.1007/s10068-012-0049-6>.
- Poli V, Madduru R, Motireddy SR, 2021. Amelioration of Cadmium-induced Oxidative Damage in Wistar Rats by Vitamin C, Zinc and N-Acetylcysteine. *Med Sci*, 10(7), 2-16. <https://doi.org/10.3390/medsci10010007>.
- Renieri EA, Safenkova IV, Alegakis A, Slutskaya ES, et al., 2019. Cadmium, lead and mercury in muscle tissue of gilthead seabream and seabass: Risk evaluation for consumers. *Food Chem Toxicol*, 124, 439-449. <https://doi.org/10.1016/j.fct.2018.12.020>.
- Satarug S, Vesey DA, Gobe GC, 2017. Current health risk assessment practice for dietary cadmium: Data from different countries. *Food Chem Toxicol*, 106(Pt A), 430-445. <https://doi.org/10.1016/j.fct.2017.06.013>.
- Satpathy S, Patra A, Purohit AP, 2013. Estrogenic activity of *Punica granatum L.* peel extract. *Asian Pac J Reprod*, 2(1), 19-24. [https://doi.org/10.1016/S2305-0500\(13\)60109-8](https://doi.org/10.1016/S2305-0500(13)60109-8).
- Shirwaikar A, Khan S, Malini S, 2003. Antiosteoporotic effect of ethanol extract of *Cissus quadrangularis* Linn. on ovariectomized rat. *J Ethnopharmacol*, 89(2-3), 245-250. <https://doi.org/10.1016/j.jep.2003.08.004>.
- Sisombath NS, Jalilehvand F, 2015. Similarities between N-Acetylcysteine and Glutathione in Binding to Lead(II) Ions. *Chem Res Toxicol*, 28(12), 2313-2324. <https://doi.org/10.1021/acs.chemrestox.5b00323>.
- Songprasert N, Sukaew T, Kusreesakul K, Swaddiwudhipong W, et al., 2015. Additional Burden of Diseases Associated with Cadmium Exposure: A Case Study of Cadmium Contaminated Rice Fields in Mae Sot District, Tak Province, Thailand. *Int J Environ Res Public Health*, 12(8), 9199-9217. <https://doi.org/10.3390/ijerph120809199>.
- Spilmont M, Léotoing L, Davicco MJ, Lebecque P, et al., 2015. Pomegranate Peel Extract Prevents Bone Loss in a Preclinical Model of Osteoporosis and Stimulates Osteoblastic Differentiation in Vitro. *Nutrients*, 7(11), 9265-9284. <https://doi.org/10.3390/nu7115465>.
- Staessen JA, Roels HA, Emelianov D, Kuznetsova T, et al., 1999. Environmental exposure to cadmium, forearm bone density, and risk of fractures: prospective population study. Public Health and Environmental Exposure to Cadmium (PheeCad) Study Group. *Lancet*, 353(9159), 1140-1144. [https://doi.org/10.1016/S0140-6736\(98\)09356-8](https://doi.org/10.1016/S0140-6736(98)09356-8).
- Tehrani A, Zarei M, Nemati Z, Esfandiyari B, et al., 2010. Investigation of physico-chemical properties and antioxidant activity of twenty Iranian pomegranate (*Punica granatum L.*) cultivars. *Sci Hortic*, 126(2), 180-185. <https://doi.org/10.1016/j.scienta.2010.07.001>.
- Trimurni A, Putra DP. Phyto Effect of *Punica granatum* on the Remodelling of Maxilla Bone, Study of Osteoblast and Osteoclast. *J Biomim Biomater Biomed Eng.*, 48, 54-61. <https://doi.org/10.4028/www.scientific.net/JBBE.48.54>.
- Trzcinka-Ochocka M, Jakubowski M, Szymczak W, Janasik B, et al., 2010. The effects of low environmental cadmium exposure on bone density. *Environ Res*, 110(3), 286-293. <https://doi.org/10.1016/j.envres.2009.12.003>.
- Uchida H, Kurata Y, Hiratsuka H, Umemura T, 2010. The effects of a vitamin D-deficient diet on chronic cadmium exposure in rats. *Toxicol Pathol*, 38(5), 730-737. <https://doi.org/10.1177/0192623310374328>.
- Wallace DR, Spandidos DA, Tsatsakis A, Schweitzer A, et al., 2019. Potential interaction of cadmium chloride with pancreatic mitochondria: Implications for pancreatic cancer. *Int J Mol Med*, 44(1), 145-156. <https://doi.org/10.3892/ijmm.2019.4204>.
- Wilson AK, Cerny EA, Smith BD, Wagh A, et al., 1996. Effects of cadmium on osteoclast formation and activity in vitro. *Toxicol Appl Pharmacol*, 140(2), 451-460. <https://doi.org/10.1006/taap.1996.0242>.
- Wu Q, Magnus JH, Hentz JG, 2010. Urinary cadmium, osteopenia, and osteoporosis in the US population. *Osteoporos Int*, 21(8), 1449-1454. <https://doi.org/10.1007/s00198-009-1111-y>.
- Yedjou CG, Tchounwou CK, Haile S, Edwards F, et al., 2010. N-acetyl-cysteine protects against DNA damage associated with lead toxicity in HepG2 cells. *Ethn Dis*, 20(1 Suppl 1), S1-101-103.
- Yogesh H, 2020. Evaluation of antiosteoporosis activity of ethanolic extract of *Punica granatum* Linn. seeds in ovariectomized-induced osteoporosis rats. *Int J Green Pharm*, 14(1), 66-72. <https://doi.org/10.22377/ijgp.v14i1.2776>.
- Zhang M, Zhang H, Li H, Lai F, et al., 2016. Antioxidant Mechanism of Betaine without Free Radical Scavenging Ability. *J Agric Food Chem*, 64(42), 7921-7930. <https://doi.org/10.1021/acs.jafc.6b03592>.
- Zhitkovich A, 2019. N-Acetylcysteine: Antioxidant, Aldehyde Scavenger, and More. *Chem Res Toxicol*, 32(7), 1318-1319. <https://doi.org/10.1021/acs.chemrestox.9b00152>.
- Zhou B, Yi H, Tan J, Wu Y, et al., 2015. Anti-proliferative effects of polyphenols from pomegranate rind (*Punica granatum L.*) on EJ bladder cancer cells via regulation of p53/miR-34a axis. *Phytother Res*, 29(3), 415-422. <https://doi.org/10.1002/ptr.5267>.

## Author Contributions

Motivation / Concept: DH, BD, HG, YK; Design: BD, YK; Control/Supervision: BD, ID; Data Collection and / or Processing: DH, MD, KF; Analysis and / or Interpretation: BD, DH, ID; Literature Review: DH, BD, MD; Writing the Article: DH, ID, MD; Critical Review: BD, HG, DH

## Ethical Approval

The animal handling and the study protocol were ethically approved by Animal Experiments Local Ethics Committee of Harran University (Approval No: 2020/003/04).