



SHORT COMMUNICATION

Surgical treatment of Paraphimosis in dogs: 4 Cases

Nuriza Zamirbekova*, Kurtulus Parlak, Iremsu Satıcı, Hilmican Ergin, Sena Yazıcı,
Ebrar Merve Eris, Melek Yıldız, Fahrettin Alkan

¹Selcuk University, Faculty of Veterinary Medicine, Department of Surgery, 42003, Konya, Türkiye

Received: 02.01.2024 , Accepted: 27.02.2024

*nuriza.zamirbekova@selcuk.edu.tr

Köpeklerde Parafimozisin cerrahi sağaltımı: 4 Olgu

Eurasian J Vet Sci, 2024, 40, 1, 41-46
DOI: 10.15312/EurasianJVetSci.2024.424

Öz

Amaç: Bu çalışma, kalıcı paraphimosis teşhisi konulan 4 köpekte, klinik semptomlara göre uygulanan cerrahi yöntemleri değerlendirmek amacıyla yapılmıştır.

Gereç ve Yöntem: Çalışma materyalini kalıcı paraphimosis teşhisi konan 4 köpek oluşturdu. Anamnez ve klinik muayene bulgularına göre 3 köpeğe idiyopatik kalıcı paraphimosis, bir köpekte ise travmatik paraphimosis tanısı konuldu. Teşhis ve bulgulara göre hastalara prepusyal ilerletme, parsiyel penil amputasyon ve preputioplasti, fallopeksi ve total penil amputasyon operasyon teknikleri uygulandı.

Bulgular: Prepusyal ilerletme operasyonu uygulanan birinci olguda operasyondan 1 hafta sonra hastalık nüks etmiştir. Kısmi penis amputasyonu uygulanan ikinci olgunun postoperatif sürecinde 3 gün boyunca devam eden aralıklı kanama tespit edildi. Üçüncü olgunun tedavisinde uygulanan prepusyal ilerletme ve fallopeksi işlemleri sonucunda herhangi bir komplikasyonla karşılaşmadı. İkinci ve üçüncü olgularda cerrahi yara iyileşme süresi bir hafta olarak kaydedildi. Dördüncü vakada operasyon sonrası 12 gün devam eden aralıklı kanama ve operasyon bölgesinde hafif dermatit kaydedildi. Operasyon sonrası 30. günde hasta sahiplerinden alınan bilgiye göre hastalığın nüksü görülmediği ve herhangi bir komplikasyona rastlanmadığı ifade edildi.

Öneri: Çalışmanın sonuçlarına göre, kalıcı parafimozis hastalarında prepusyumdan prolabe olan penisin uzunluğu 1,5 cm veya daha fazla ise prepusyal ilerletme operasyon tekniğinin tek başına yetersiz olduğu görüldü. Ayrıca penis gövdesi ve üretradaki bozukluğun izin verdiği durumlarda, total penil amputasyon yerine kısmi penil amputasyonu tercih edilmelidir.

Anahtar kelimeler: Köpek, parafimozis, cerrahi müdahale

Abstract

Aim: The aim of this study was to evaluate the use of surgical methods concerning the severity of persistent paraphimosis and describe the surgical techniques.

Materials and Methods: The study material consisted of 4 dogs with paraphimosis. Based on anamnesis and clinical examination, 3 dogs were diagnosed with idiopathic permanent and one dog with traumatic paraphimosis. According to diagnoses and findings, patients underwent preputial advancement, partial penile amputation, phallopexy, and total penile amputation.

Results: Recurrence of disease 1 week following surgery was recorded as postoperative complication in the first patient with preputial advancement. Intermittent bleeding in the surgical field in the second patient undergoing partial penile amputation continued for 3 days. No complications were observed as a result of the preputial advancement and phallopexy procedures performed for the treatment of the third case. The surgical wound healing time was recorded as one week in the second and third cases. In the fourth case, intermittent bleeding persisted for 12 days postoperatively and mild dermatitis was noted at the surgical site. According to the information received from the patient owners on the 30th day after the surgery, it was noted that there was no recurrence of the disease and no complications were encountered.

Conclusion: According to the results of our study preputial advancement surgery technique alone was unsuccessful when the length of the prolapsed penis from the prepuce was 1,5 cm or more in patients with permanent paraphimosis. In addition, in cases where the disorder of the penile shaft and urethra allows, partial penile amputation should be preferred to total penile amputation.

Keywords: Dog, paraphimosis, surgery

CITE THIS ARTICLE: Zamirbekova et al 2024. Surgical Treatment of Paraphimosis in Dogs: 4 Cases Eurasian J Vet Sci, 40, 1, 41-46.



Introduction

Paraphimosis in dogs is defined as an inability of the penis to fully retract into the prepuce for any reason. It is most commonly seen in young unneutered male dogs, but it has also been reported in neutered male dogs and, rarely, in cats (Kustritz and Olson 1999, Somerville and Anderson 2001). Primary paraphimosis usually occurs in young dogs as a result of excessive sexual activity. Secondary paraphimosis can also be caused by the hypoplastic foreskin, trauma, copulation, masturbation, penile haematoma, small or stenotic preputial orifice, entanglement and compression of preputial hair, dysfunction of preputial muscles unable to retract the penis into the foreskin, hypospadias, and posterior paralysis. It can also develop as balanoposthitis, penile tumors, priapism, or idiopathies (Kustritz 2001, de la Puerta and Baines 2012, Aydın ve ark 2022, Ritson et al 2023). Prognosis and treatment options for paraphimosis are suggested using criteria such as clinical symptoms, duration, and severity. In the early stages of paraphimosis, penile tissue appears normal and is painless. Circulatory problems, colour changes, and loss of sensitivity in the penis can occur if the glans is under constant pressure. The problem aggravates when the dog licks and bites the penis tissue exposed to the external environment, leading to increased edema and circulatory problems. In long-term paraphimosis, the glans may lose sensitivity, the urethra may become blocked and the penis may become necrotic. Surgeons diagnose paraphimosis by physical examination of the penis prolapsed from the prepuce. The entire length of the penis should be examined in detail to determine whether the animal has any other urogenital abnormalities (Olsen and Salwei 2001). If urination is present and no urethral rupture is observed during the examination, the penis should be inserted into the prepuce as soon as possible to prevent recurrence. If rejection of the penis into the prepuce is unsuccessful, various surgical techniques should be recommended (Olsen and Salwei 2001, Fossum 2013). These techniques include the application of constricting sutures to the preputial orifice, preputioplasty, cranial preputial advancement, preputial muscle myorrhaphy, and phallopey (Papazoglou 2001).

Depending on the extent of the penile lesion or trauma, complete or partial penile amputation may be performed. Complete resection of the penis and prepuce may be combined with scrotal urethrostomy (de la Puerta and Baines 2012, Fossum 2013).

In this study, we present the clinical findings and surgical results of 4 male dogs with paraphimosis that were brought to Selçuk University, Faculty of Veterinary Medicine, Department of Veterinary Surgery, Small Animal Clinical Sciences.

Material and Methods

Study design and patient preparation

Three cases, in which conservative paraphimosis treatment was attempted but failed, were included in the study. In the fourth case, penile trauma was interpreted as the cause of paraphimosis. In these four cases, the paraphimosis was considered permanent and treated surgically. Pre-operative urethral catheterisation was used to protect the urethra and prevent damage during surgery in the second and fourth cases. The patients were followed for a period of 2 weeks to 3 months. No surgery was required for minor post-operative complications. Due to the recurrence of the first case after the first surgery, a second surgical intervention was carried out. The same surgeon performed all operations. Routine clinical, haematological, and biochemical analyses were performed on all patients prior to surgery. Unneutered dogs were castrated with the consent of the patient's owner (Figure 4-C). Patients were fasted for 12 hours prior to surgery.

Case 1: The first case was an 11-month-old, weighing 20 kg, neutered male grey cross-breed dog. According to the patient's history, the penis had been permanently prolapsed for 2 months. The length of the prolapsed penis from the preputial orifice was measured as 1,5 cm (Figure 1-A). It recurred after previous conservative treatment and narrowing of the preputial orifice. On physical examination, the penis was flaccid and the mucous membranes were pale pink and dry. There were no trauma-related findings and no tumor tissue was found in the penis or prepuce. When the prepuce was pulled cranially by manual manipulation, it easily covered the penis. The decision was made to perform a prepusal advancement surgery, as the condition did not respond to conservative treatment and persisted for approximately 2 months.

Preputial advancement: A crescent-shaped skin incision was made just cranial to the preputial skin. The subcutaneous connective tissue was carefully dissected to expose the preputial muscles. An automatic Gelpi retractor was placed in the area and the preputial muscles were overlapped and sutured. The subcutaneous tissue and skin were then routinely closed (Figure 1-B) (Fossum 2013).

Case 2: The second case was a 3-year-old, weighing 28 kg, unneutered black cross-breed male dog. The patient's history revealed that permanent paraphimosis had been present for one year and preputioplasty had been used as a treatment, but was unsuccessful. On physical examination, the mucosa of the prolapsed part of the penis was very dry and the colour ranged from pale pink to white with the inverted prepuce. A demarcation line was observed in the penis due to narrowing of the preputial orifice. No pathology was found in the penile or preputial tissues. The length of the prolapsed penis was measured as 4 cm. Treatment included partial penile amputation and castration.

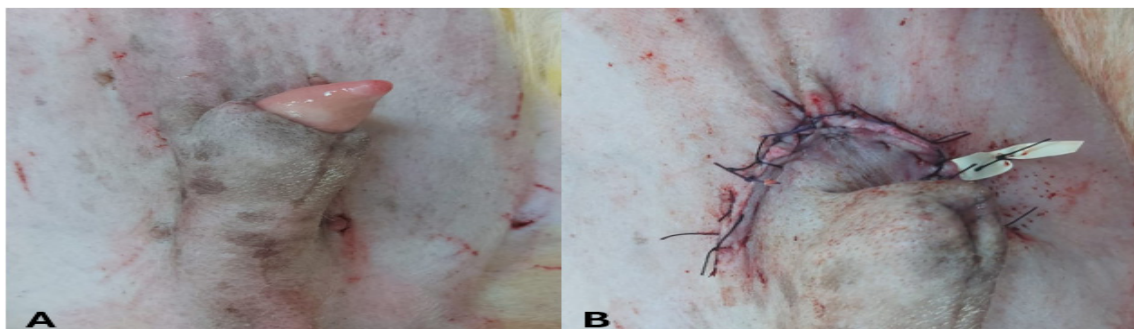


Figure 1. A) Permanent paraphimosis in an 11-month-old dog. B) Postoperative appearance of preputial advancement procedure.

Partial penile amputation: A urethral catheter was placed in the patient to facilitate urethral monitoring and to prevent urethral trauma. The penis was removed from the prepuce and a tourniquet was placed caudally via the Penrose drain to the intended amputation site (Figure 2-A). A V-shaped incision was made along the tunica albuginea and cavernous tissue on both sides of the urethra and os penis. Taking care not to traumatise the urethra, the os penis was cut as caudally as possible using a bone cutter. The tourniquet was released, and bleeding sites were identified and ligated. The urethra was transected 1 to 2 cm from the penile transection site. The urethral mucosa was then sutured to the tunica albuginea layer of the penis with interrupted sutures. The cavernous tissue was also passed with each suture (Figure 1-B). After partial penile amputation, preputioplasty was performed to adapt the length of the prepuce to the length of the penis (Fossum 2013, Arican 2022).

Case 3: The third case was a neutered black and white male cross-breed dog 18 months old and weighing 17 kg. The patient had persistent paraphimosis for 3 months. Clinical examination revealed a 2 cm prolapse of the penis, paleness, and dryness of the mucosa (Figure 3-A). No pathological formation of the prepuce or penis was observed. Surgical treatment included cranial preputial advancement and phallopey.

Phallopey: A skin incision was made parallel to the prepuce at the junction of the prepuce and skin. The incision was extended caudally for 2 to 3 cm. The penis was pulled laterally. A preputial mucosa was removed from the dorsal midline of the preputial lumen, starting 3 cm caudal to the preputial orifice, in a strip 0,5 cm wide and 1,5 cm long. The penile shaft was then brought out through the preputial orifice. A strip of mucosa, 0,5 cm wide and 1,5 cm long, was removed from the dorsal midline of the middle part of the glans penis, starting 2 cm caudal to the apex. The penis was repositioned in the prepuce and the incisions from the prepuce to the penis were sutured with 4/0 monofilament absorbable suture (Figure 3-E). The preputial mucosa, subcutaneous connective tissue, and skin were routinely closed (Fossum 2013, Arican 2022). The preputial advancement procedure was performed as described previously (Figure 3-B,C,D).

Case 4: The fourth case was a 2-year-old unneutered grey cross-breed male dog weighing 35 kg. The patient's owner reported that the dog had been missing for a week and when found, the penile area was necrotic. According to the history, the patient was predicted to have a penile trauma. Clinical and cytological examination of the patient showed no evidence of TVT. The prepuce tissue was hyperemic and hypertrophic, and necrotic areas were noted in the penile tissue. The patient underwent complete penile amputation and scrotal urethrostomy (Figure 4-D).

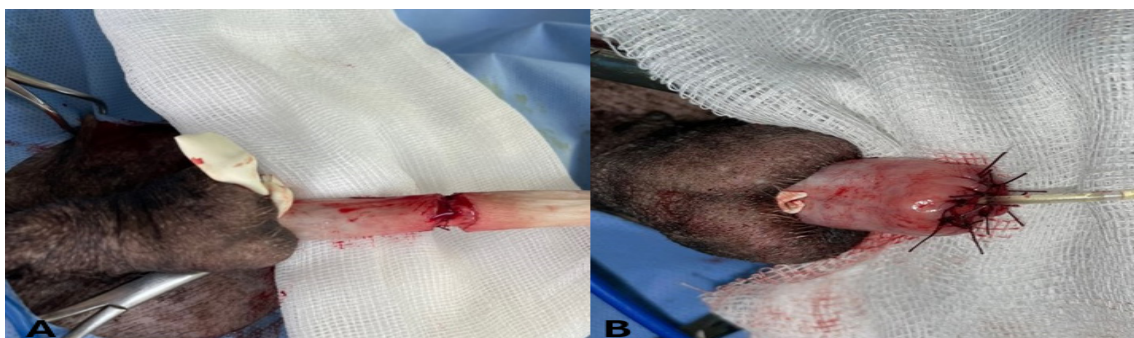

Figure 2. Intraoperative image of partial penile amputation. A) Retracting the prepuce, applying a tourniquet to the penis, making the lateral incisions, and suturing the urethra to the tunica albuginea. B) The urinary catheter is visible and the urethra is fully sutured to the tunica albuginea.



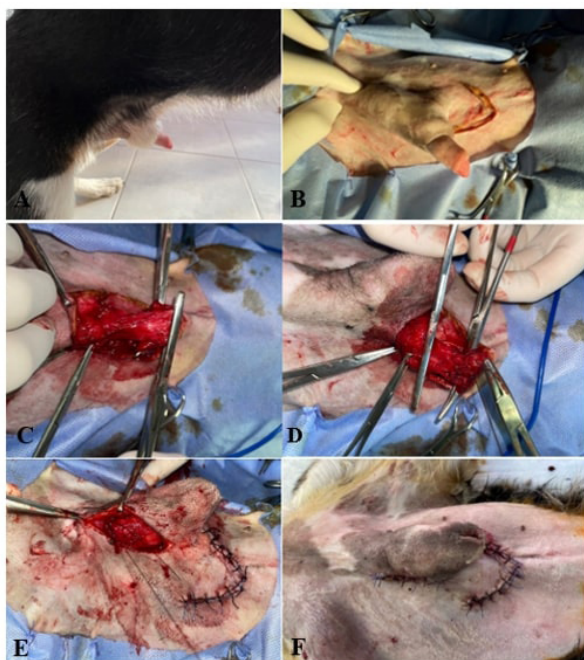


Figure 3. A) Inverting the prepuce and protruding the glans penis. B) Resection of a crescent-shaped piece of skin. C) Identifying the preputial muscle. D) Overlapping preputial muscle and suturing. E) Approximate the penile and preputial incisions with simple interrupted sutures. F) Postoperative appearance.

Complete Penil Amputation: Prior to the total amputation, the patient had been routinely neutered. An urethral catheter was inserted. An elliptical incision was made on the skin, covering the area around the prepuce and the scrotum. Subcutaneous connective tissue was dissected. Superficial epigastric blood vessels were ligated. Then, the spermatic cords were isolated and resected. The penis was dissected caudally towards the scrotum. The prepuce, penis, os penis, and scrotum were resected. Subcutaneous connective tissue and skin were routinely sutured down to the scrotum. A urethral incision at least five times the diameter of the urethra was made to ensure that the urethral stoma was of sufficient size in the scrotal region. The urethral mucosa was sutured to the skin with simple separate sutures (Figure 4-D) (de la Puerta and Baines 2012).

Anaesthetic Protocol

Sedation was provided with medetomidine HCl (Domitor®, Zoetis, Turkey) 0,04 mL/kg, IM (Kuusela et al 2001), and butorphanol 0,2 mg/kg, IM Propofol (Propofol-Lipuro 1%, B. Braun, Germany) 1-4 mg/kg IV was administered to the dogs for induction of anaesthesia. For intubated patients, isoflurane was administered in a dose range of 2-3%. During surgery, fluid (Ringer laktate) support was provided at a rate of 5-10 mL/kg/h for more than 30 min, depending on the anaesthetic combination. Depth of anaesthesia, heart and respiratory rates, oxygen saturation, end-tidal CO₂ (ETCO₂), temperature, blood pressure, and mucosal colour were monitored throughout the operation (Taylor and Smeak 2021).

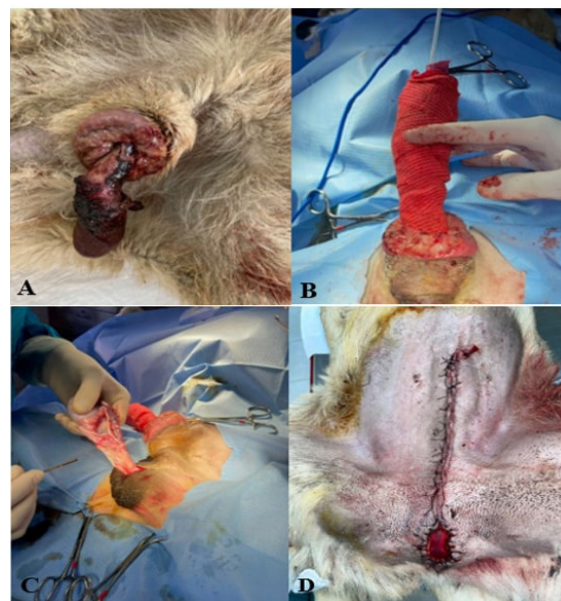


Figure 4. A) Post-traumatic penile necrosis. B) Urethral catheter placement. C) Exposing the spermatic cord for neutering. D) Resected prepuce, penis, os penis, and scrotum and applying simple sutures for suturing urethral mucosa to skin.

The surgical site was shaved and routinely disinfected in all patients. Patients were placed on the table in the ventrodorsal position. The hind limbs were fixed in the frog-leg position. The prepuce was thoroughly rinsed with sterile saline and the surgical areas were draped.

Meloxicam (0,1 mg/kg, SC, QD, (Maxicam, Verano, Turkey) was used for pain control and was continued for the next 5 days postoperatively. Cefazolin (20 mg/kg, IM, BID, (Sefazol, Mustafa Nevzat, Turkey) was used after surgical intervention as antibiotic prophylaxis for 7 days. All patients received an intramuscular injection of H₂-receptor antagonist ranitidine 1 mg/kg twice daily to protect from possible side effects of meloxicam on the stomach for 5 days. To prevent patients from licking themselves during the post-operative period, an Elizabethan collar was worn.

Results

The disease recurred in the preputial advancement operation of the first case. As a result, the patient underwent a second surgery (fallopexy). Post-operative bleeding in a second patient undergoing partial amputation of the penis continued for 3 days. There were no complications from the preputial advancement and phallopexy performed in the third case. In the second and third cases, the surgical wound healing time was recorded as one week. In the fourth case, post-operative haemorrhage continued for 12 days with mild dermatitis noted in the surgical area. The patient's hospitalization was recorded as 15 days. No complications or recurrence of the disease were noted according to the



information received from the patients' owners on the 30th day after surgery.

Discussion

Paraphimosis is a condition caused mainly by an abnormal small preputial orifice, dysfunction of the preputial muscles or a hypoplastic prepuce, trauma, infection, neoplasia, prolonged erection, or idiopathies (Chaffee and Knecht 1975, Koc and Alkan 2001, Papazoglu 2001).

Acute cases of penile paraphimosis occur clinically with severe oedema, hyperemia, and pain. Conservative methods are usually successful in managing such cases. Three of the paraphimosis cases treated in this case study had permanent paraphimosis findings such as pale and painless penile colours, without oedema, the persistence of more than 2 months with being unresponsive to conservative treatments (Adeola and Enobong 2016).

No findings were suggesting congenital anomalies such as aplastic or hypoplastic prepuce, narrow preputial orifice, or a tumor mass (Papazoglu 2001). The first, second, and third cases were classified as idiopathic and the fourth case as traumatic paraphimosis based on the information from the patients' owners and physical examination findings. Cranial preputial muscle insufficiency and penile retractor muscle inefficiency have been suggested as causes of idiopathic paraphimosis (Johnston 1989).

In the literature, various surgical methods as well as partial and/or total amputation of the penis are recommended for the treatment of permanent paraphimosis, penile trauma, and penile tumors. In this study, a variety of surgical techniques were used to successfully treat four dogs diagnosed with persistent paraphimosis. The selection of the surgical method was based on the results of the patient's examination and the authors (de la Puerta and Baines 2012). Phallopey is considered successful for acute paraphimosis and penile protrusion not exceeding 1.5 cm. In cases where the phallopey method is insufficient alone, preputial advancement technique is recommended. In the revision surgery of our first case, the phallopey was applied in addition to the preputial advancement technique (Somerville and Anderson 2001, Fossum 2013). Successful results were reported in the study in which the preputial advancement technique applied alone. The researcher emphasised that surgical treatment of paraphimosis using the preputial advancement technique may be effective when the length of the exposed penis is 1,5 cm or less (Papazoglu 2001). Both preputial advancement and phallopey techniques were applied for the treatment of paraphimosis in the third case. No postoperative complication or recurrence were observed.

Ritson et al (2023) successfully performed partial penile amputation in 10 dogs diagnosed with paraphimosis. The researchers emphasized that the complication rate of partial penile amputation was lower than that of total penile amputation. The study reported that two out of ten dogs developed urethral stricture and underwent revisional surgery. One of the two patients undergoing partial penile amputation had less postoperative intermittent bleeding and a shorter hospital stay than the patient undergoing total penile amputation. Regional inflammation and pain after surgery lasted only two days. There was no skin irritation. No wound-healing complications or urethral stenosis were observed (Ritson et al 2023).

The fourth patient underwent total penile amputation due to severe trauma to the penis and prepuce. As reported in previous studies (Burrow et al 2011), intermittent bleeding during and after urination continued for 12 days in the postoperative period. Wound healing took longer compared to partial penile amputation, phallopey, and preputial advancement surgery. Mild dermatitis was also noted. The patient was examined 3 months after the operation and was found to be able to continue daily life without any problems. There were no findings in the haematological and biochemical analyses which would have prevented the patients from undergoing surgery.

Conclusion

In this study, different surgical methods were used to treat 4 patients diagnosed with permanent paraphimosis. The diagnosis of the disease was based on the patient's history, physical examination, and the degree of penile involvement. Based on the results of our study, preputial advancement surgery alone is not sufficient in cases where the length of the prolapsed penis from the prepuce was 1,5 cm or more. According to our observation, the partial penile amputation method is superior to the total penile amputation method due to shorter recovery time, less postoperative bleeding and absence of surgical site complications. Therefore, if the condition of persistent paraphimosis is suitable for partial penile amputation, this method should be preferred to avoid complications after total penile amputation.

The main limitation of our study was a non-uniform with a small number of patients, so a standardised treatment could not be applied.

Conflict of Interest

The authors did not report any conflict of interest or financial support.



References

- Adeola BS, Enobong H, 2016. Surgical management of paraphimosis in Dog: A case report. *Glob Vet*, 16(1), 49-51. <https://doi.org/10.5829/idosi.gv.2016.16.01.101160>.
- Arıcan M, 2022. Üriner Sisteme Cerrahi Yaklaşımlar. Kedi ve Köpeklerde Abdominal Cerrahi. Anka Promosyon Matbaa Mlz. Ltd. Şti. Karatay, Konya, 430-444.
- Aydin U, Karakurt E, Dağ S, Beytut E, et al., 2022. Clinical and immunohistochemical evaluation of penile tumors in bulls. *J. Adv. Vetbio Sci. Tech* 7(2), 210-219. <https://doi.org/10.31797/vetbio.1086702>.
- Burrow RD, Gregory SP, Giejda AA, White RN, 2011. Penile amputation and scrotal urethrostomy in 18 dogs. *Vet Rec*, 169(25), 657-657. <https://doi.org/10.1136/vr.100039>.
- Chaffee VW, Knecht CD, 1975. Canine paraphimosis: Sequel to inefficient preputial muscles. *Vet Med Small Anim Clin*, 70, 1418-1420.
- de la Puerta B, Baines S, 2012. Surgical diseases of the genital tract in male dogs 2. Penis and prepuce. *Companion Anim Pract*, 34(3), 128-135. <https://doi.org/10.1136/inp.e1102>.
- Fossum TW, 2013. Surgery of The Male Reproductive Tract, In: *Small Animal Surgery*, Ed: Fossum TW, Dewey CW, Horn CV, Johnson AL, Radlinsky MG, Schulz KS, Mac Phail CM, Willard MD, 4th edition, Elsevier, Mosby, Missouri, p. 849-853.
- Johnston SD, 1989. Disorders of the external genitalia of the male. In: *Textbook of Veterinary Internal Medicine*, 2nd edition, Ed S. J. Ettinger. W. B. Saunders, Philadelphia, p.1881-1889.
- Koc K, Alkan F, 2001. The Evaluations of Testis, Penis and Prepuce Diseases in Domestic Animals. *Vet Bil Derg*, 17(4), 67-74.
- Kustritz MV, Olson PN, 1999. Theriogenology question of the month. Priapism or paraphimosis. *J Am Vet Med Assoc*, 214, 1483-1484.
- Kustritz MVR, 2001. Disorders of the canine penis. *Vet Clin N Am*, 31(2), 247-258. [https://doi.org/10.1016/S0195-5616\(01\)50203-X](https://doi.org/10.1016/S0195-5616(01)50203-X).
- Kuusela E, Raekallio M, Väisänen M, Mykkänen K, et al., 2001. Comparison of medetomidine and dexmedetomidine as premedicants in dogs undergoing propofol-isoflurane anesthesia. *Am J Vet Med Res*, 62(7), 1073-1080. <https://doi.org/10.2460/ajvr.2001.62.1073>.
- Olsen D, Salwei R, 2001. Surgical correction of a congenital preputial and penile deformity in a dog. *J Am Anim Hosp Assoc*, 37, 187-192. <https://doi.org/10.5326/15473317-37-2-187>.
- Papazoglou LG, 2001. Idiopathic chronic penile protrusion in the dog: a report of six cases. *J Small Anim Pract*, 42(10), 510-513. <https://doi.org/10.1111/j.1748-5827.2001.tb02459.x>.
- Ritson K, Bird F, Stefanidis G, Brissot H, 2023. The indications, complications and outcomes of dogs undergoing partial penile amputation: 10 cases (2014-2021). *J Small Anim Pract*, 64(2), 103-110. <https://doi.org/10.1111/jsap.13564>.
- Somerville ME, Anderson SM, 2001. Phallopey for treatment of paraphimosis in the dog. *Journal of the J Am Vet Med Assoc*, 37, 397-400. <https://doi.org/10.5326/15473317-37-4-397>.
- Taylor CJ, Smeak DD, 2021. Perineal urethrostomy in male dogs—Technique description, short-and long-term results. *Can Vet J*, 62(12), 1315.

Author Contributions

Motivation / Concept: FA, KP, NZ; Design: FA, KP, NZ; Control/ Supervision: KP, NZ; Data Collection and / or Processing: HE, IS, MY, EME; Analysis and / or Interpretation: HE, IS; Literature Review: NZ, KP; Writing the Article: FA, KP, NZ; Critical Review: FA, KP

Ethical Approval

Selcuk University Experimental Research and Application Center, 30.11.2023, 2023/43 Number Ethics Committee Decision.